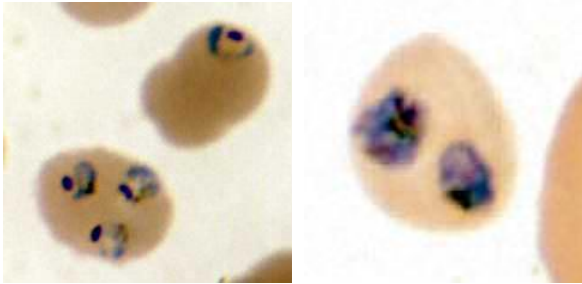
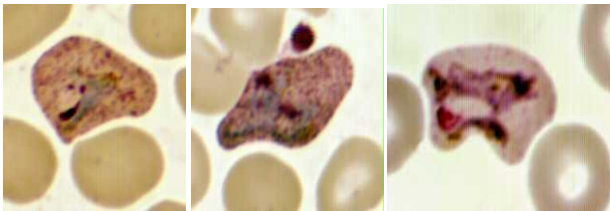


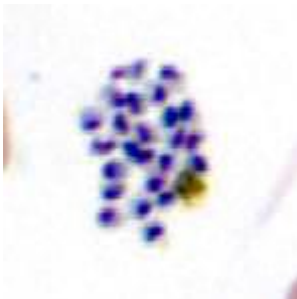Imágenes



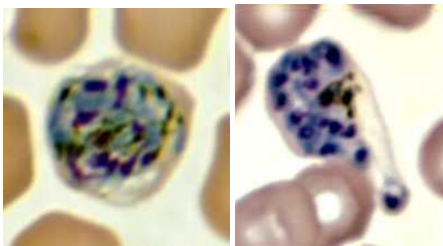
***Plasmodium falciparum*: Trofozoitos.**



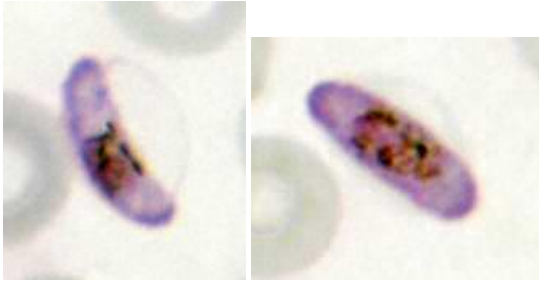
***Plasmodium vivax*. Trofozoitos.**



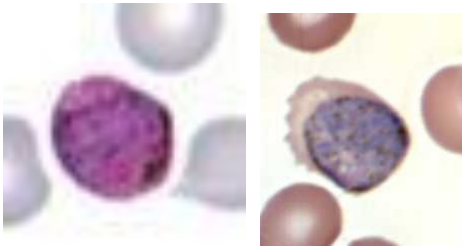
***P. falciparum*. Esquizonte maduro.**



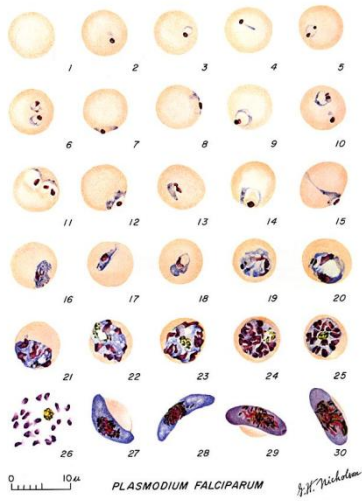
***Plasmodium vivax*. Esquizontes.**



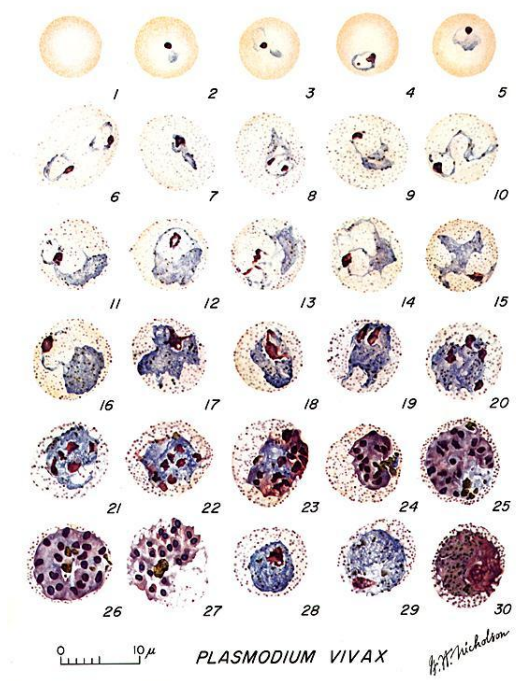
***Plasmodium falciparum*: Gametocitos.**



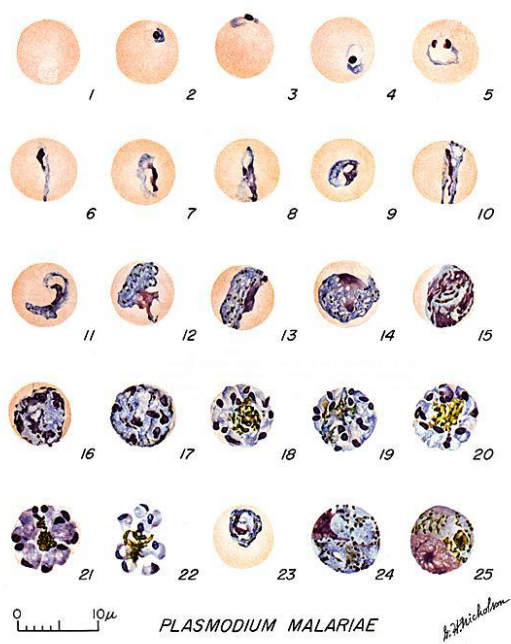
***Plasmodium vivax*: Gametocitos.**



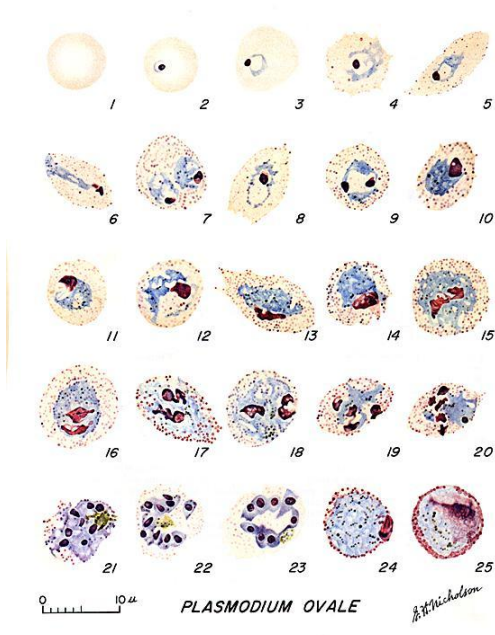
***Plasmodium falciparum*. Estadios en sangre.**



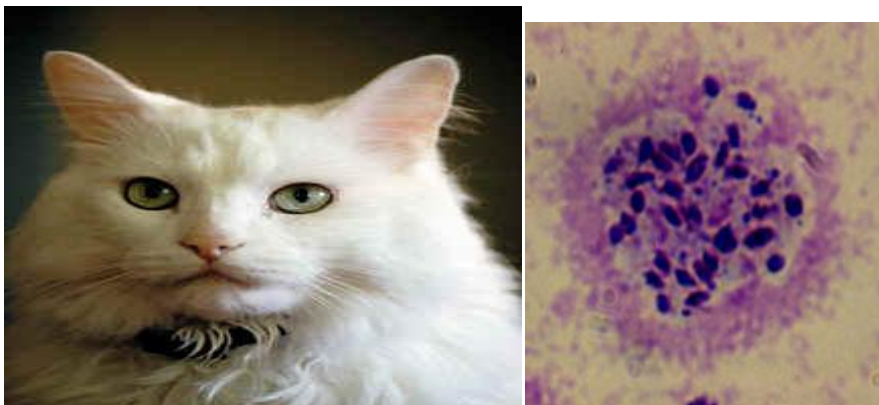
Plasmodium vivax. Estadios en sangre.



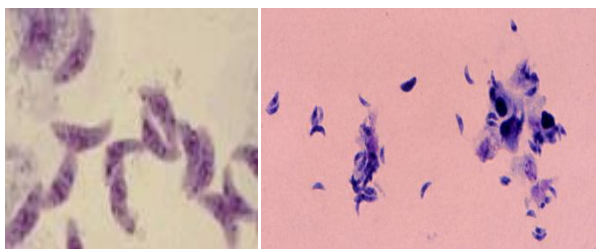
Plasmodium malariae. Estadios en sangre.



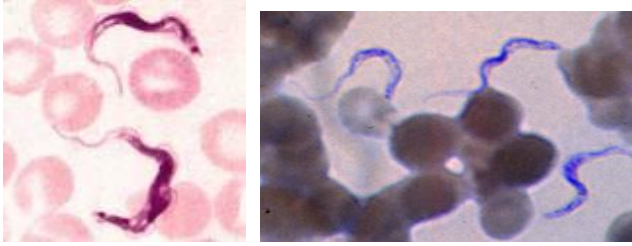
Plasmodium ovale. Estadios en sangre.



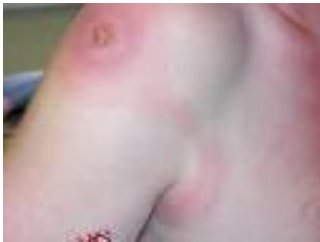Toxoplasma gondii. Quistes en tejidos de gato.



Toxoplasma gondii. Trofozoitos.



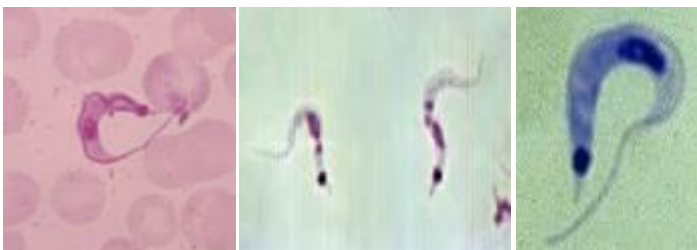***Trypanosoma brucei*. Tripomastigote.**



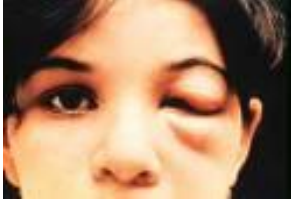***Trypanosoma brucei*. Chancro tripanosómico.**



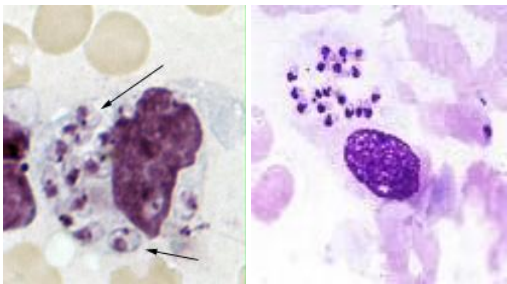
***Trypanosoma brucei*. Enfermedad del sueño.**



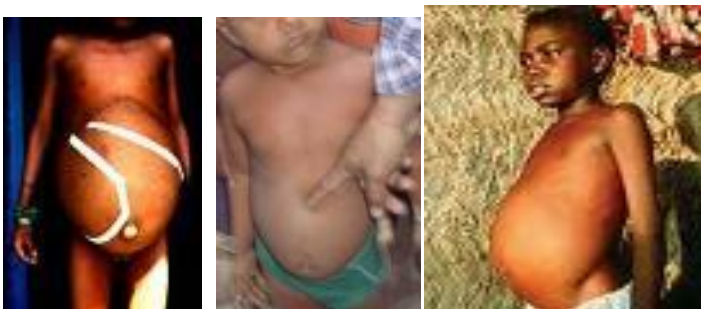
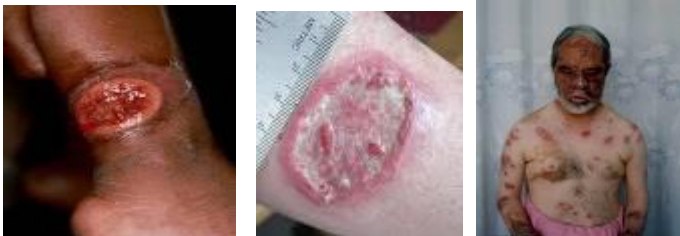
***Trypanosoma cruzi*. Tripomastigotes.**



***Trypanosoma cruzi*. Signo de Mazza Romaña.**



***Leishmania*. Amastigote.**



***Leishmania*. Fotos de enfermos.**



***Pneumocystis carinii*. Trofozoitos.**



***Pneumocystis carinii*. Quistes.**

