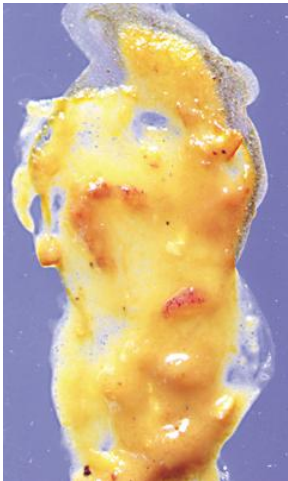
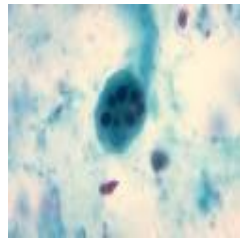
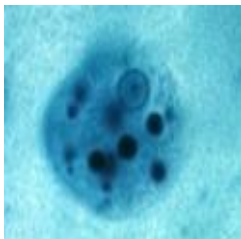
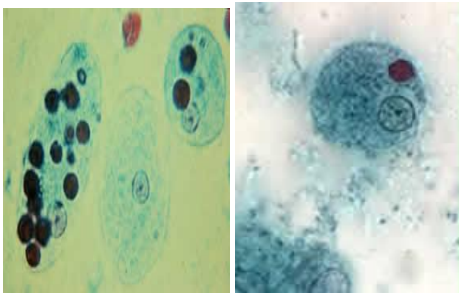


Imágenes Protozoos

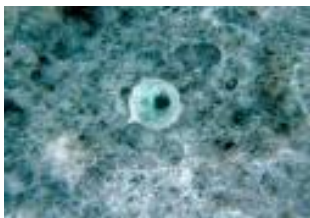

E. histolytica

Presencia de heces diarreicas con contenido de mucus y sangre.



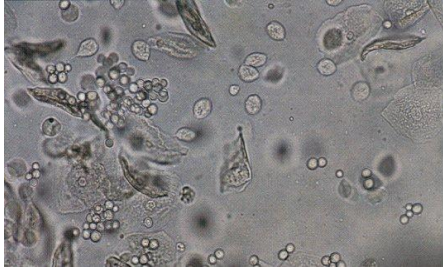
Entamoeba histolytica. Trofozoitos con eritrocitos fagocitados.



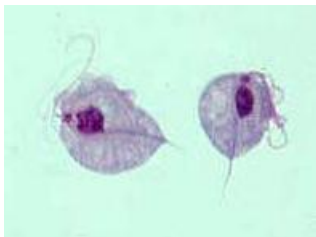Entamoeba histolytica. Prequiste.



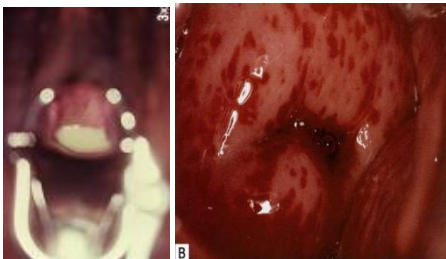***Entamoeba histolytica*. Quiste tetranucleado.**



***Trichomonas vaginalis*. Trofozoitos en examen directo.**



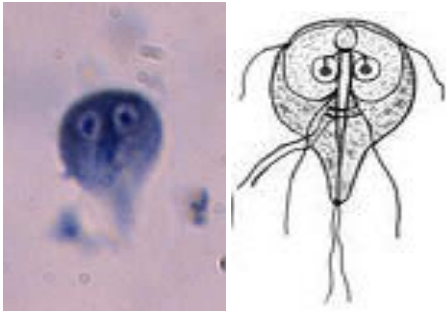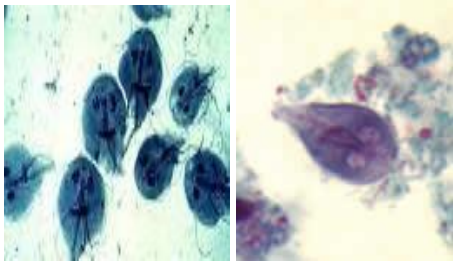
***Trichomonas vaginalis*. Trofozoitos obtenidos en cultivo in vitro.**



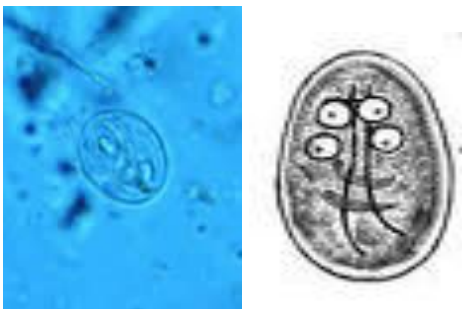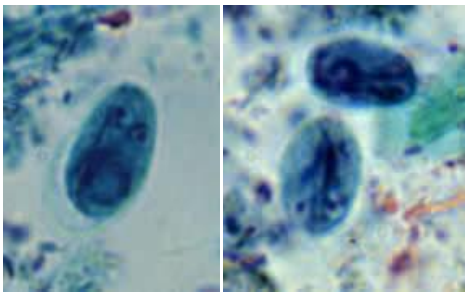
***Trichomonas vaginalis*. En la mujer.**



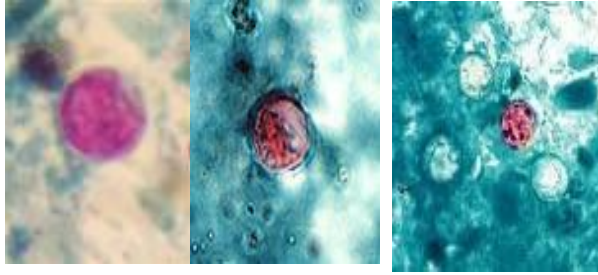
***Trichomonas vaginalis*. En el hombre.**



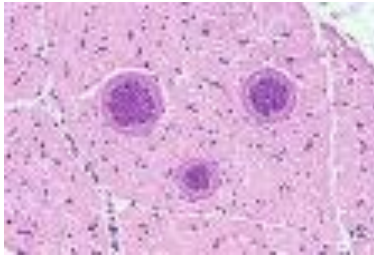
***Giardia lamblia*. Trofozoitos. Examen directo y dibujo.**



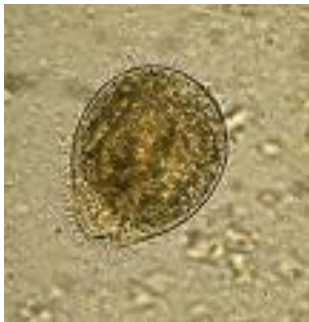***Giardia lamblia*. Quistes. Examen directo y dibujo.**



***Cyclospora*. Ooquistes.**



***Sarcocystis*.**



***Balantidium coli*. Trofozoito.**