

Sistema Nervioso

Sumario:

- Indicación del estudio imagenológico para los síndromes del sistema nervioso.
- Anatomía radiográfica del cráneo. Sistemática del estudio de cráneo simple.
- TAC Simple de cráneo: Definición de imágenes hipodensas e hiperdensas.
- Imagenología en el estudio de los síndromes del sistema nervioso: Hipertensión endocraneana, Meníngeo, Convulsivo, Hemipléjico, Cefalea.

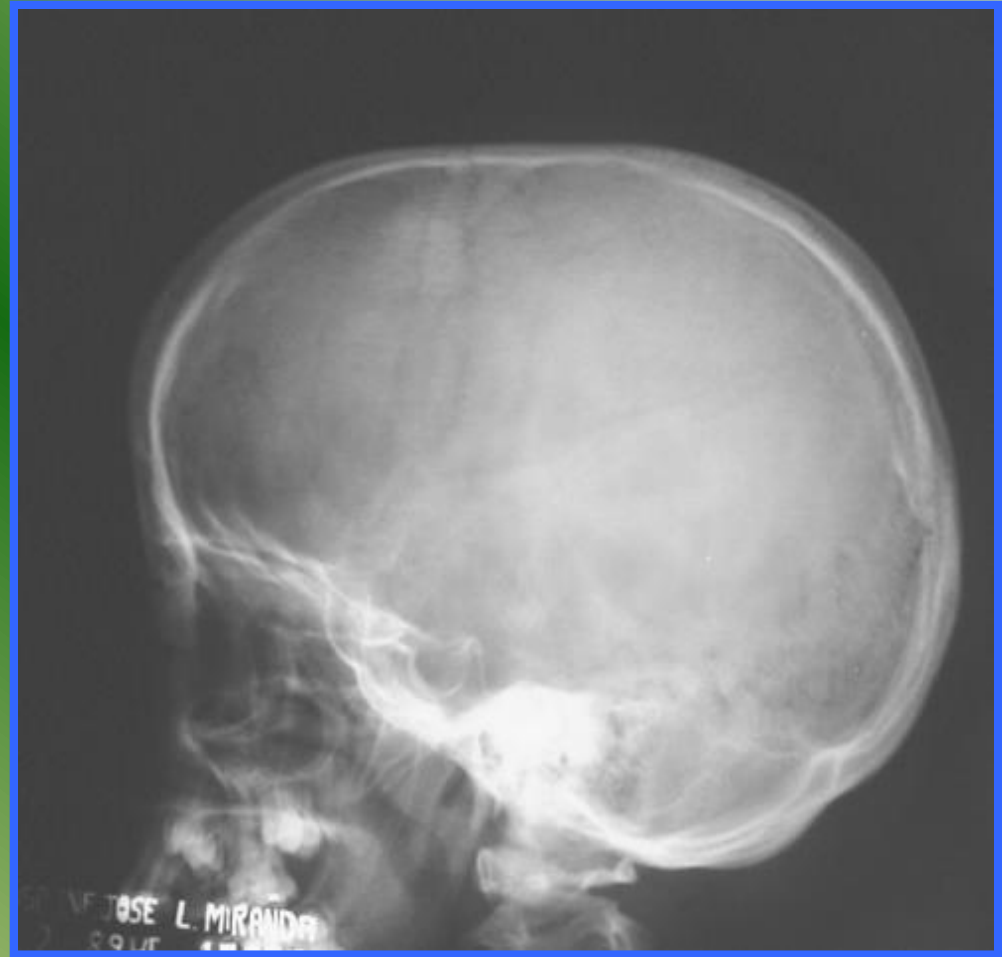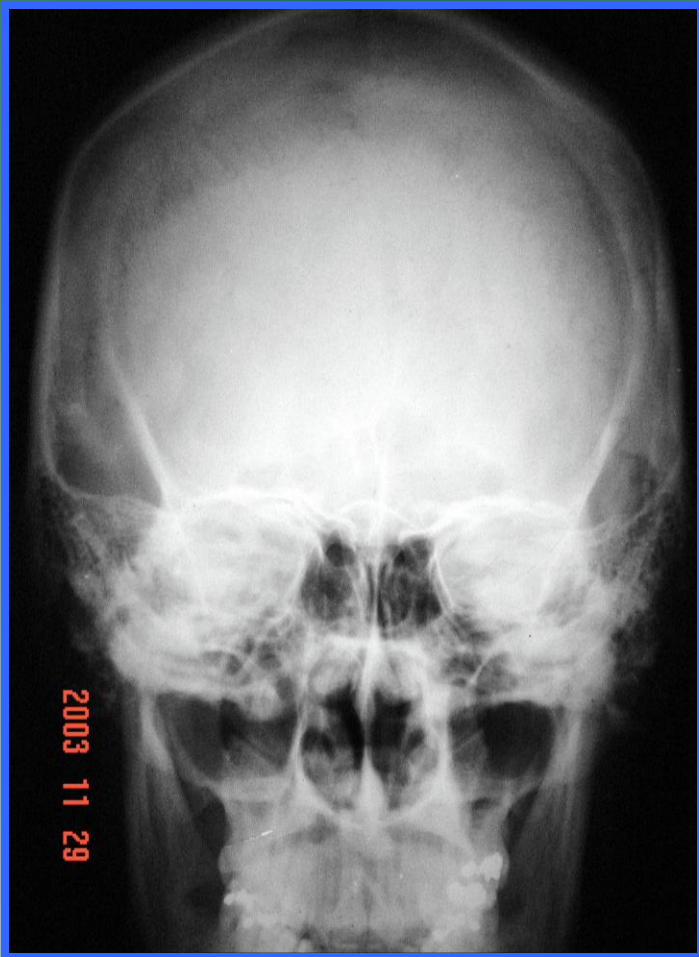Objetivos:

- 1. Indicar los estudios imagenológicos al alcance del médico general básico, partiendo de la hipótesis diagnóstica creada, ante pacientes reales o simulados.
- 2. Interpretar el estudio de cráneo simple, tomando en cuenta los datos clínicos del paciente.
- 3. Integrar los resultados de los estudios ofrecidos por el imagenólogo al proceso diagnóstico de los síndromes del sistema nervioso.

Exámenes Imagenológicos

- Rx Cráneo Simple.
- TAC.
- RMN.
- US Doppler.
- Opacificaciones vasculares.

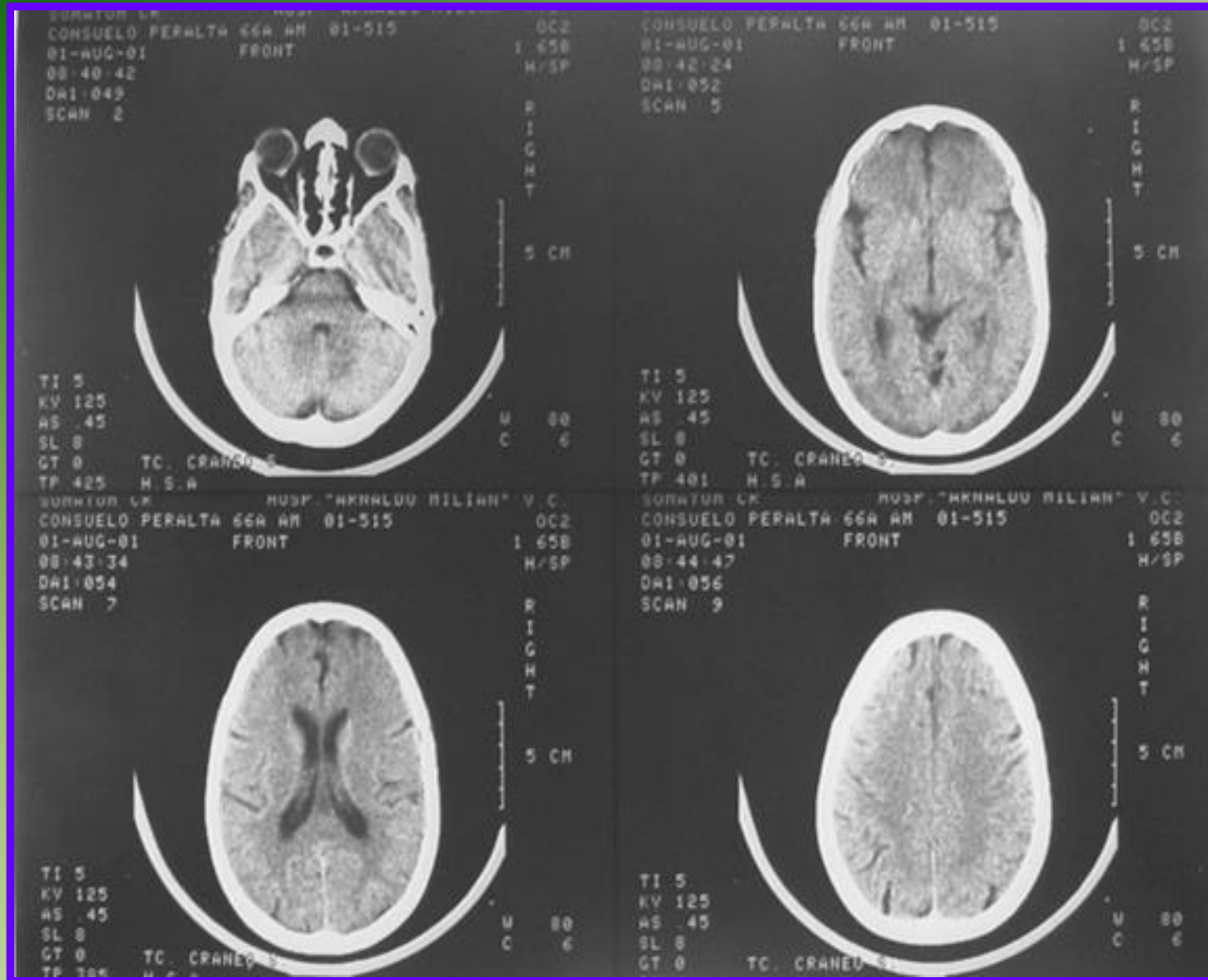
Cráneo Simple



TOMOGRAFIA AXIAL COMPUTARIZADA

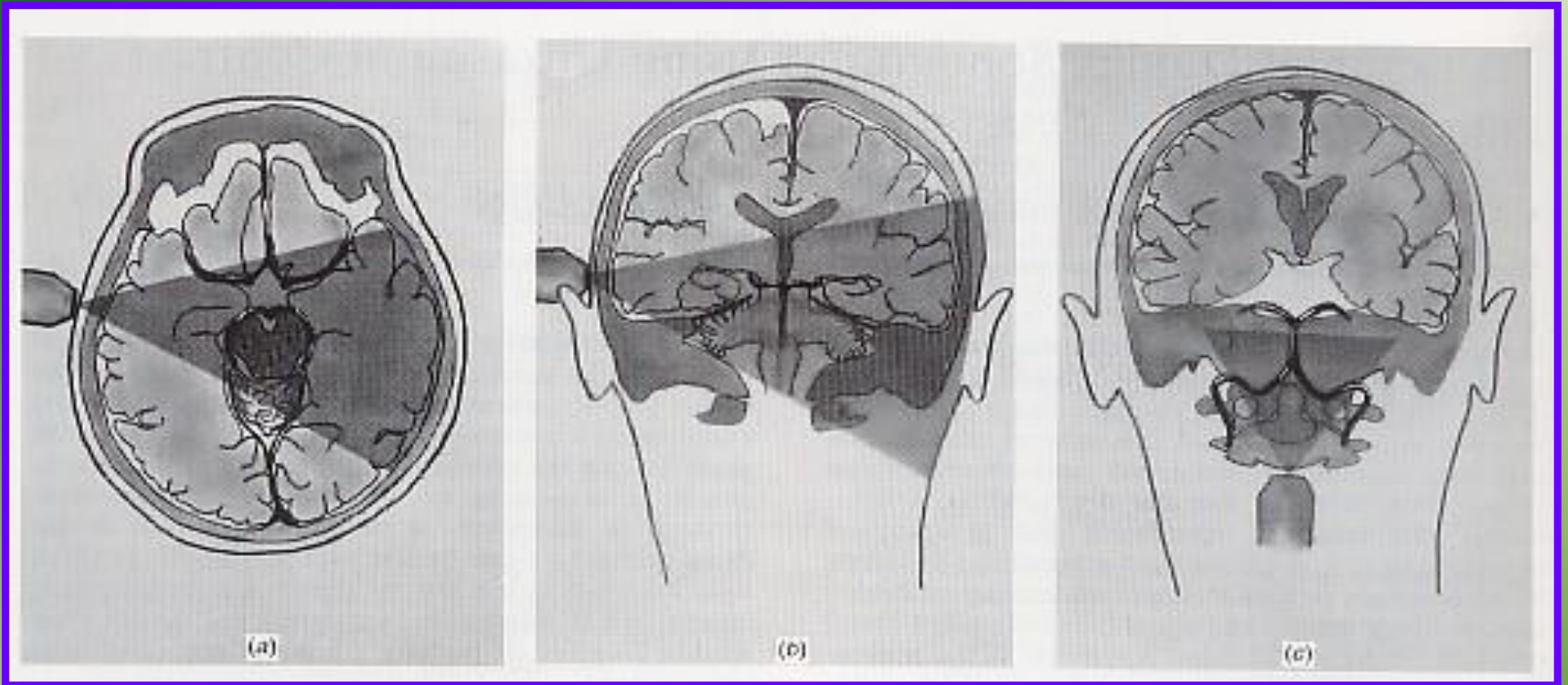


TAC

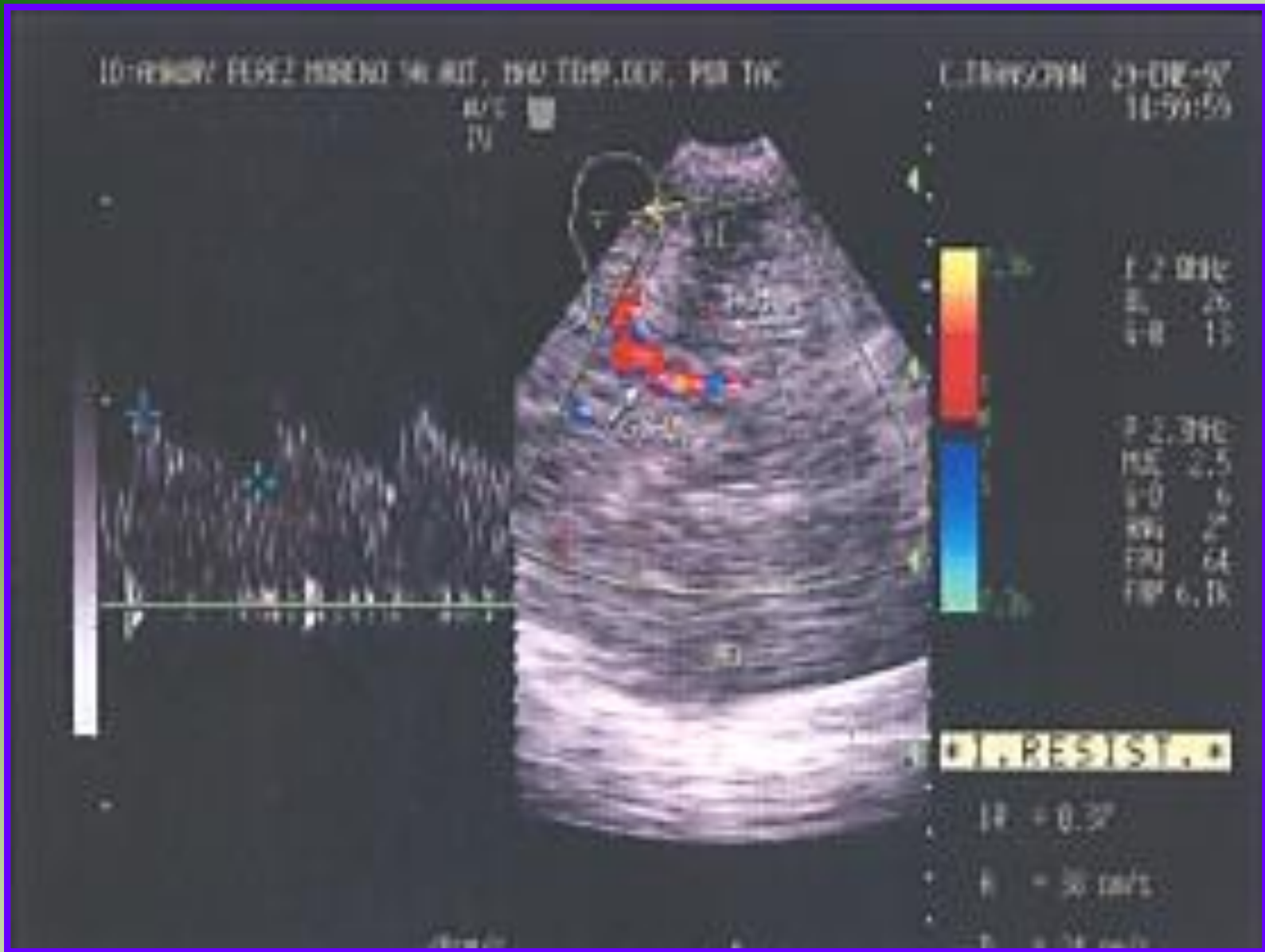

US Doppler



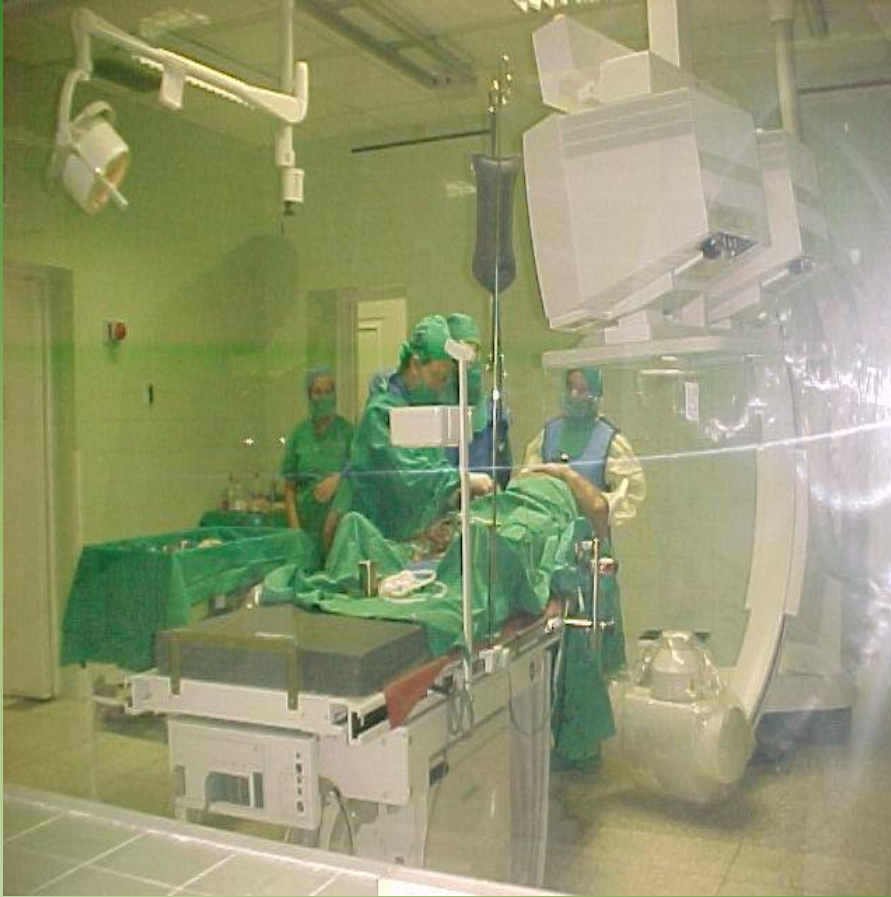

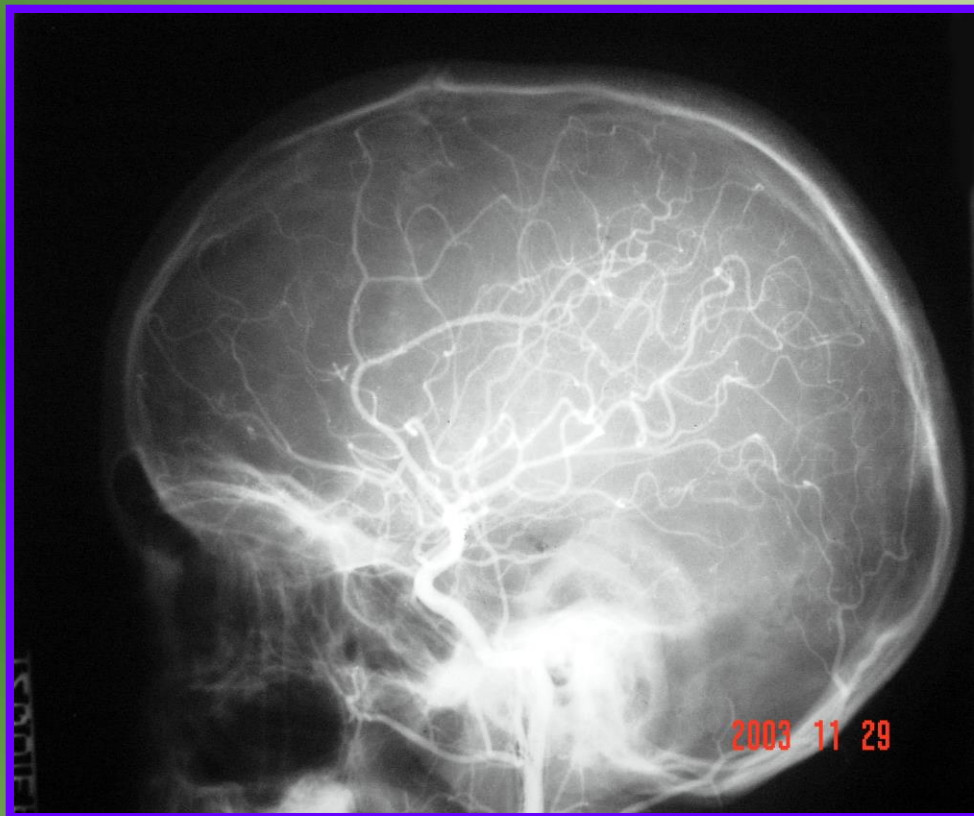
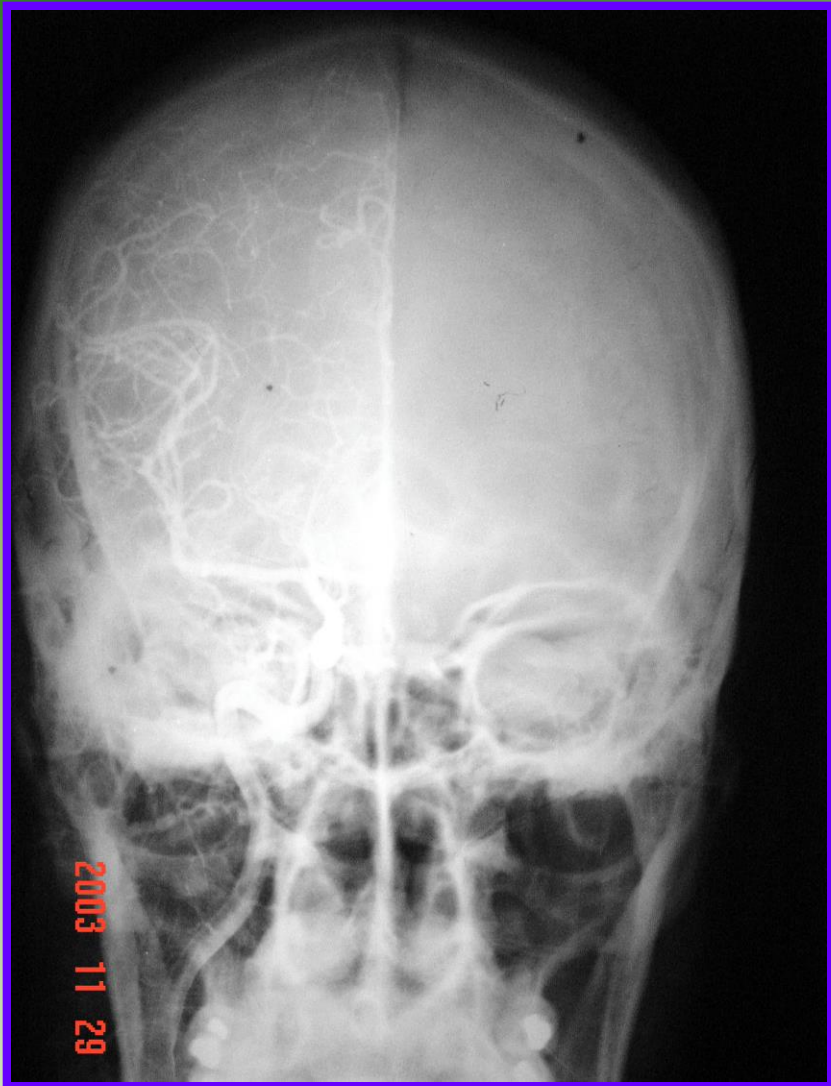Ecografía Transfontanelar, via escama del hueso temporal y via agujero magno.



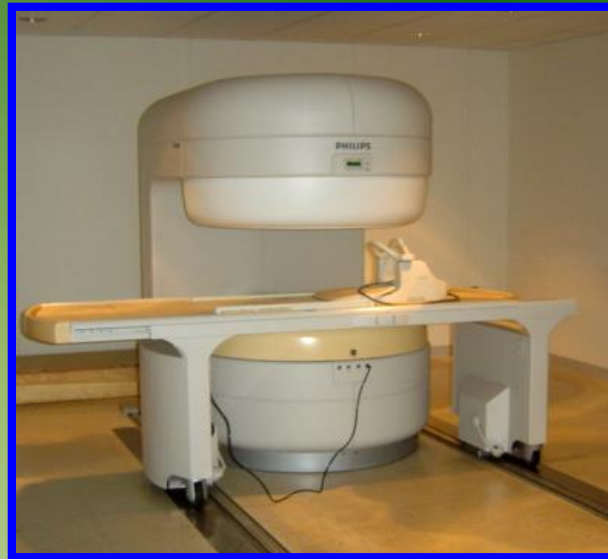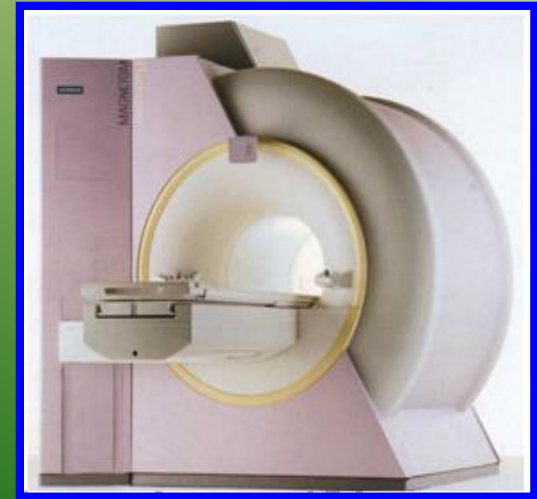
DOPPLER TRANSCRANEALE

Opacificaciones Vasculares

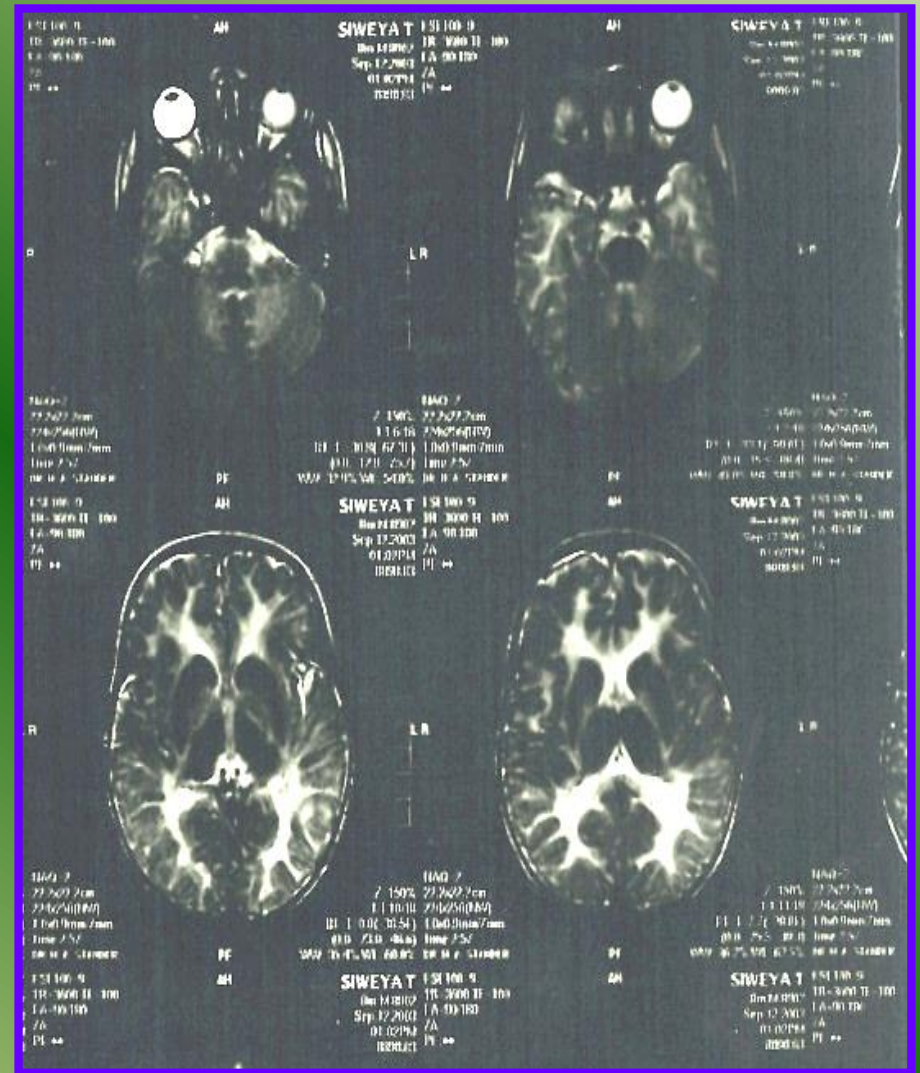
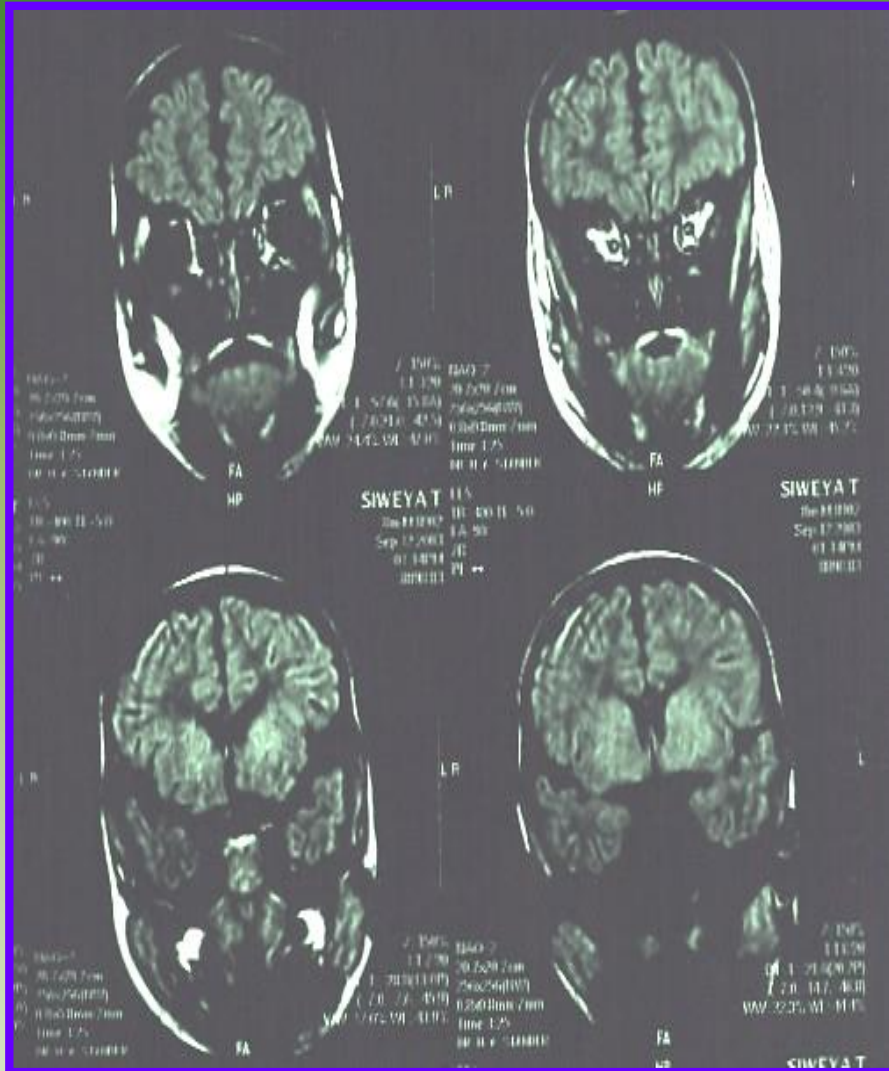




RESONANCIA MAGNETICA NUCLEAR

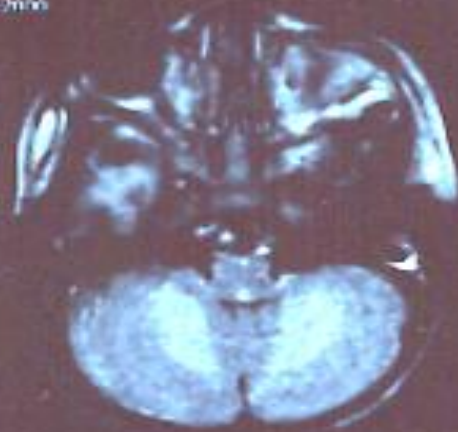

RESONANCIA MAGNETICA NUCLEAR



FSI 120 T1
TR=10000 TI=120
FA=90.100 TI=2000
73
PT=++

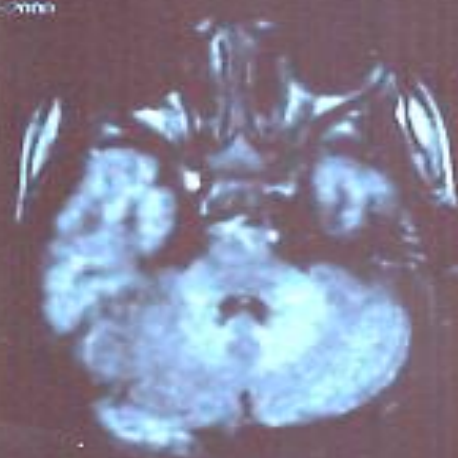AH



SIWEYA T
08.14.0002
Sep.12.2000
01.07394
1890101

FSI 120 T1
TR=10000 TI=120
FA=90.100 TI=2000
73
PT=++

AH



SIWEYA T
08.14.0002
Sep.12.2000
01.07394
1890101

R

LR

HAQ-7
22.4x22.4cm
22.4x25.6(100%)
1.0x0.9mm/3mm
Time:0.50
08.14.0002

PF

AH

Z: 150%
L1:10.20
CT: [35.0] [-75.21]
[7.0] [11.1] [11.1]
Time:0.50
WW:50.0% WL: -40.0%

SIWEYA T
08.14.0002
Sep.12.2000
01.07394
1890101

HAQ-7
22.4x22.4cm
22.4x25.6(100%)
1.0x0.9mm/3mm
Time:0.50
08.14.0002

PF

AH

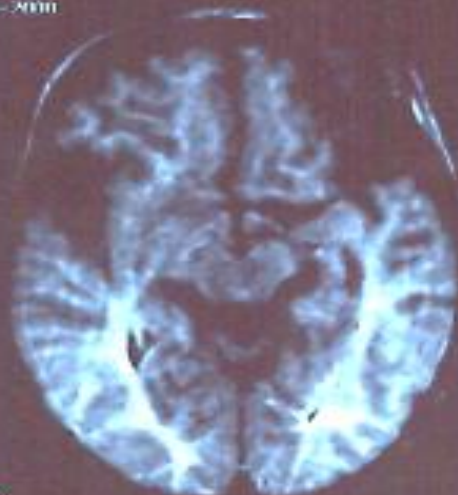
Z: 150%
L1:11.28
CT: [20.0] [88.3]
[7.0] [11.0] [16.2]
Time:0.50
WW:50.0% WL: -40.0%

SIWEYA T
08.14.0002
Sep.12.2000
01.07394
1890101

FSI 120 T1
TR=10000 TI=120
FA=90.100 TI=2000
73
PT=++

PF

AH



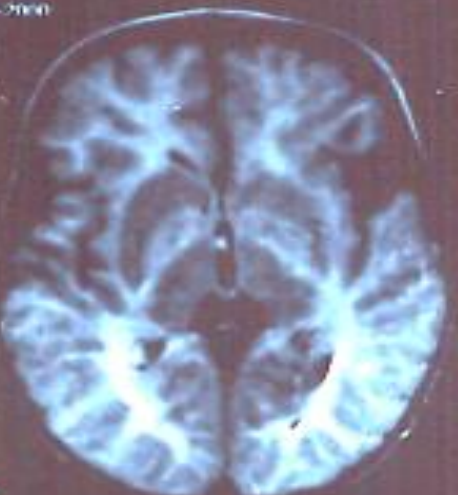
FSI 120 T1
TR=10000 TI=120
FA=90.100 TI=2000
73
PT=++

LR

FSI 120 T1
TR=10000 TI=120
FA=90.100 TI=2000
73
PT=++

PF

AH



FSI 120 T1
TR=10000 TI=120
FA=90.100 TI=2000
73
PT=++

HAQ-7
22.4x22.4cm
22.4x25.6(100%)
1.0x0.9mm/3mm
Time:0.50
08.14.0002

PF

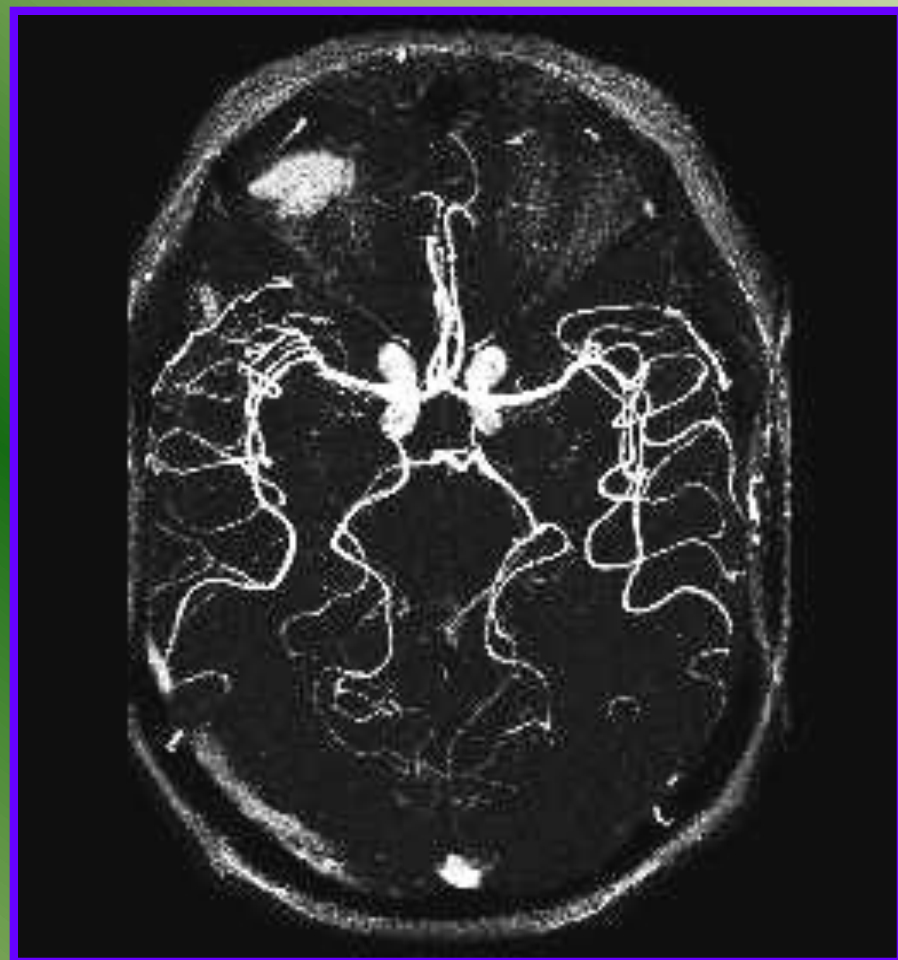
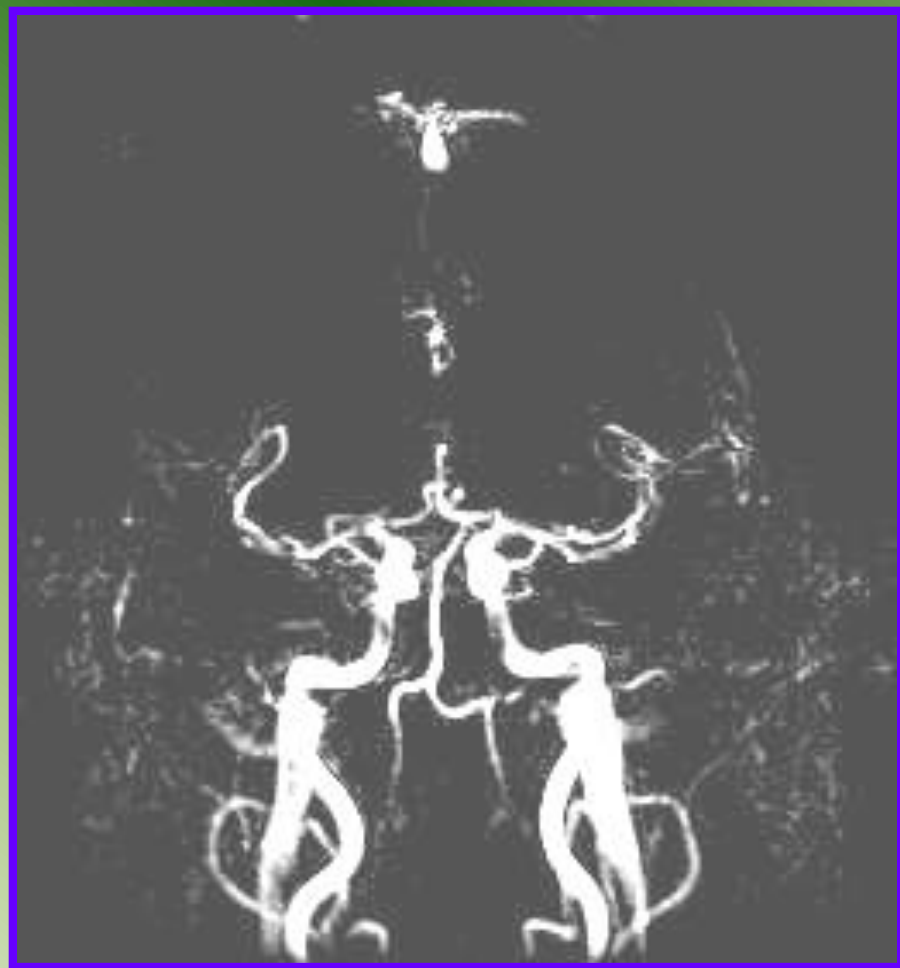Z: 150%
L1:10.20
CT: [7.0] [25.5] [-56.1]
[7.0] [25.5] [-56.1]
Time:0.50
WW:50.0% WL: -50.0%

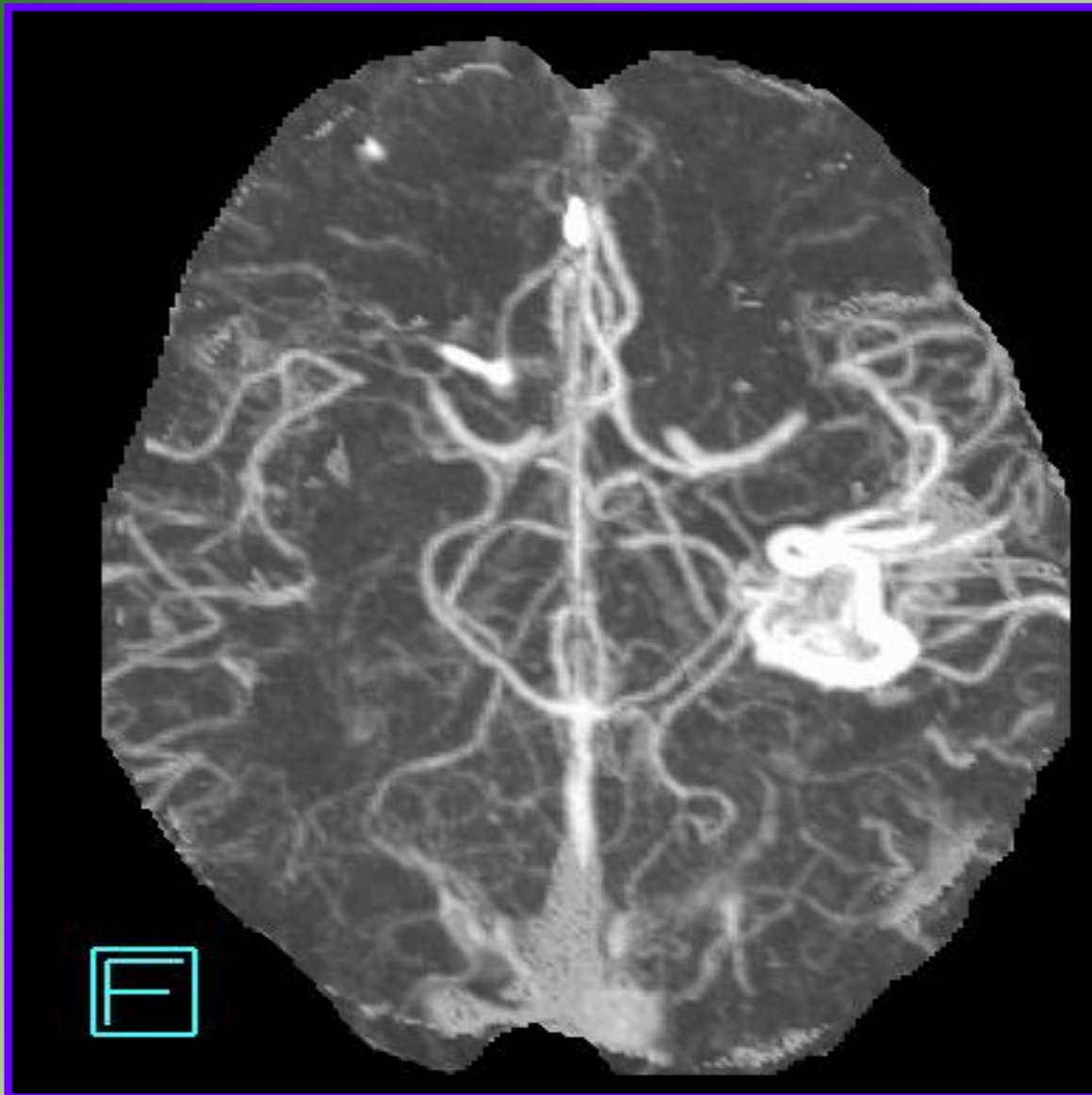
HAQ-7
22.4x22.4cm
22.4x25.6(100%)
1.0x0.9mm/3mm
Time:0.50
08.14.0002

PF

Z: 150%
L1:11.28
CT: [6.0] [-40.2]
[7.0] [27.4] [-81.1]
Time:0.50
WW:50.0% WL: -100.0%

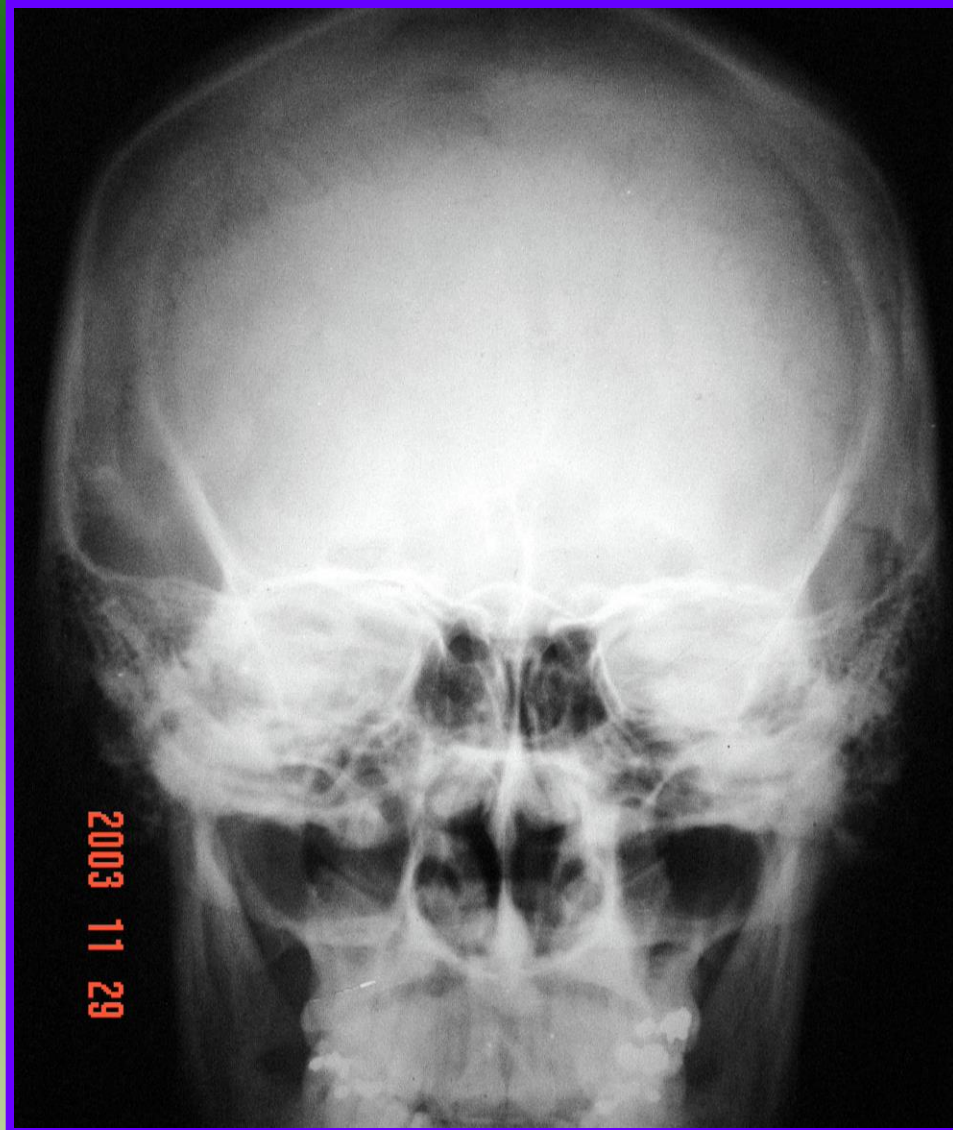SIWEYA T
08.14.0002
Sep.12.2000
01.07394
1890101



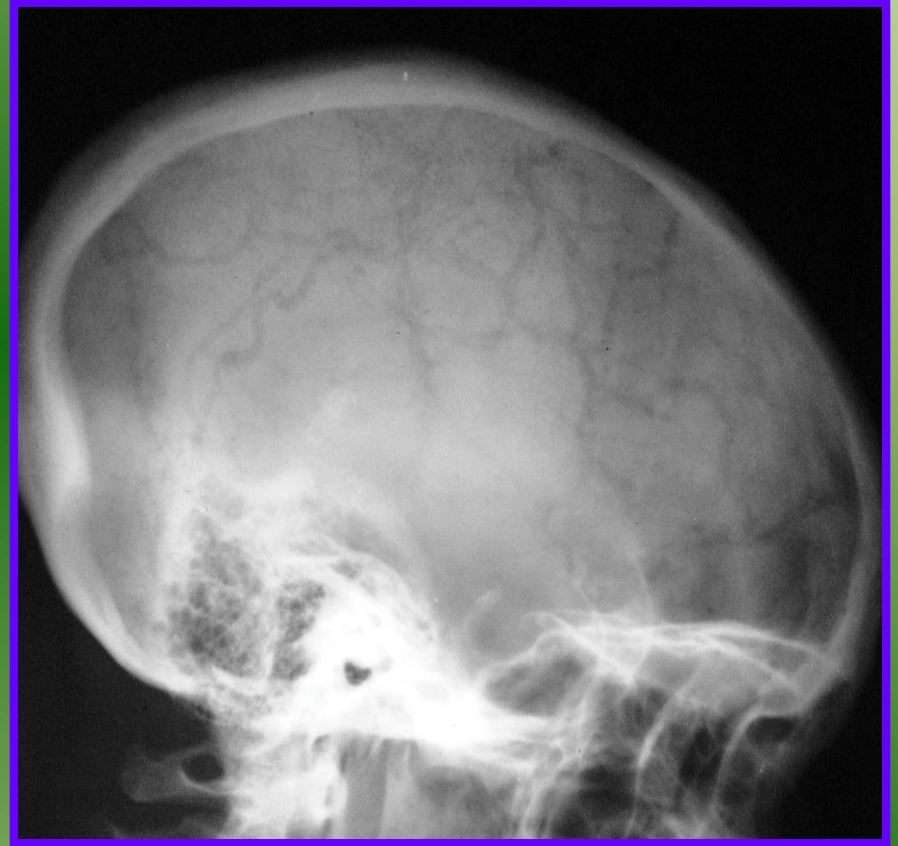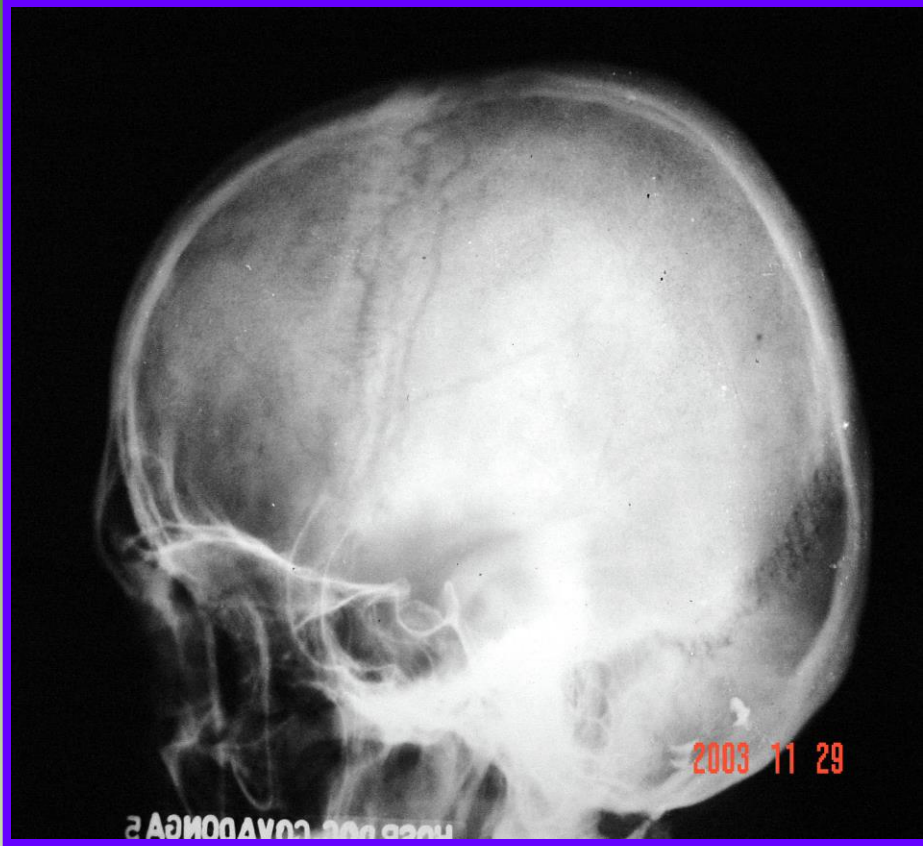


Cráneo Simple

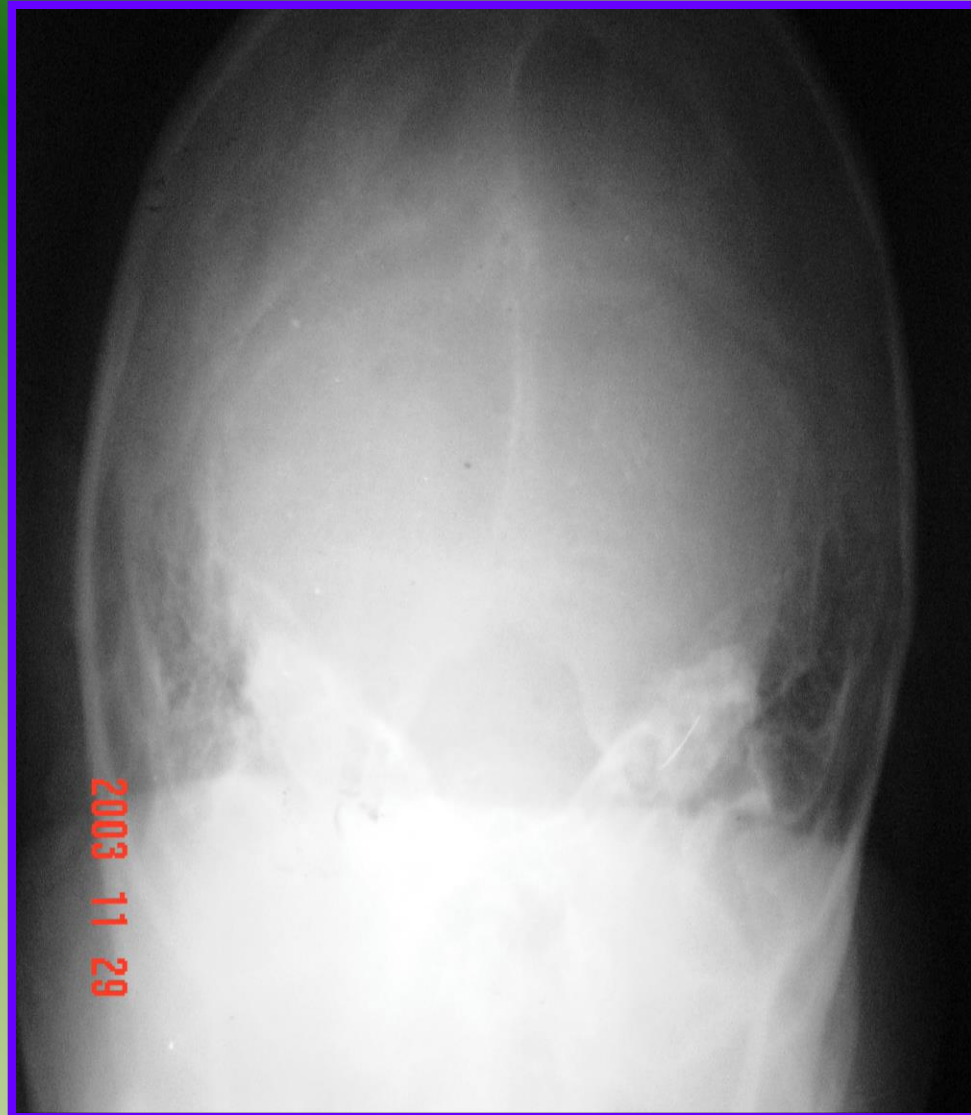Cráneo Simple AP



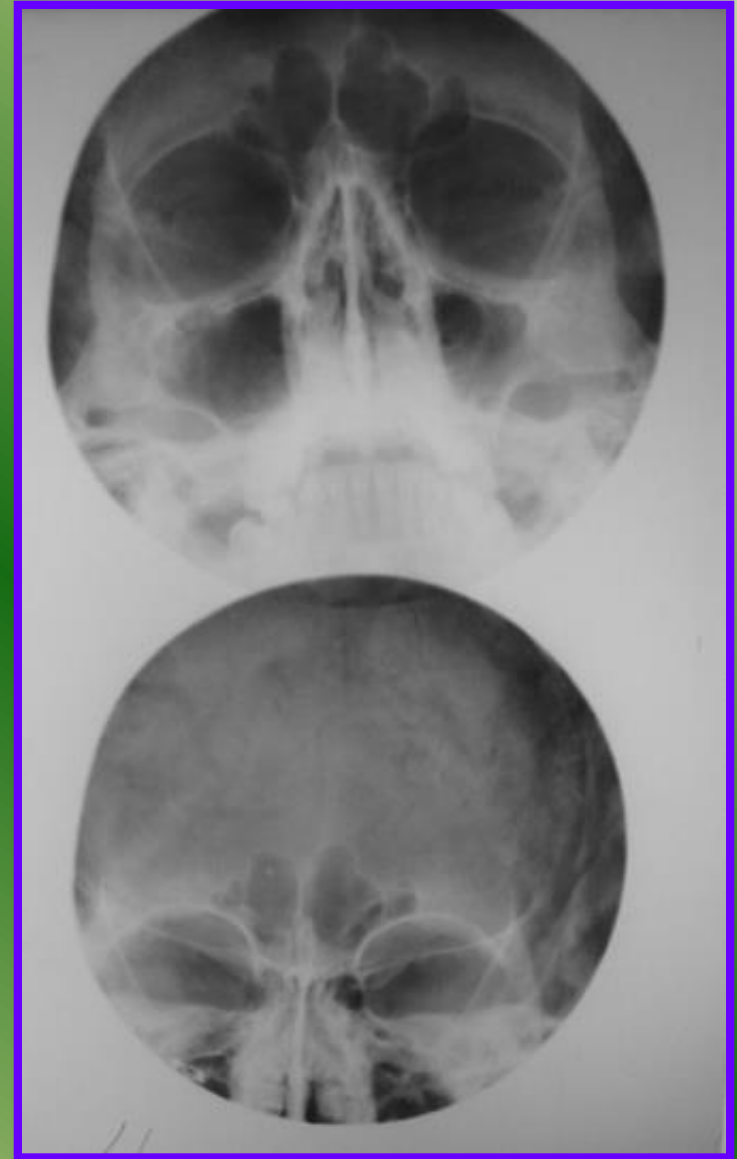
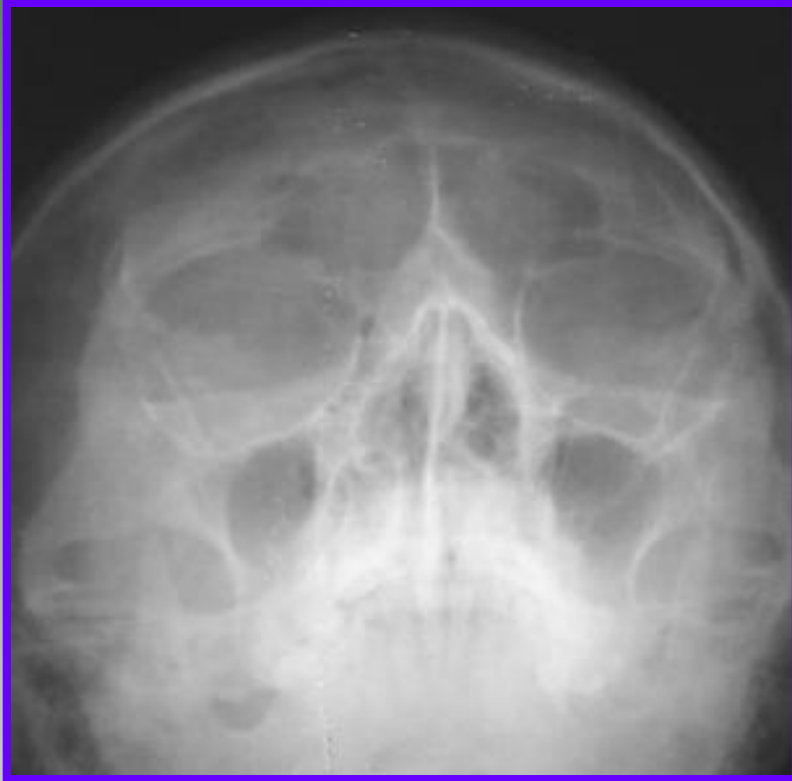Cráneo Simple Lateral



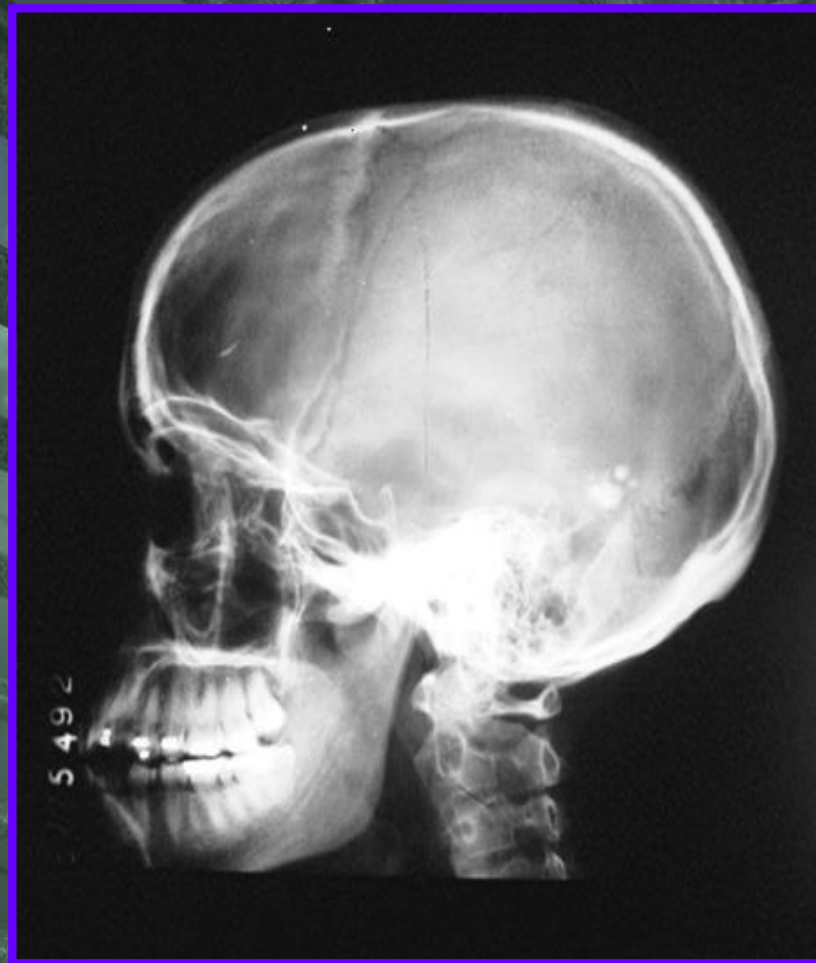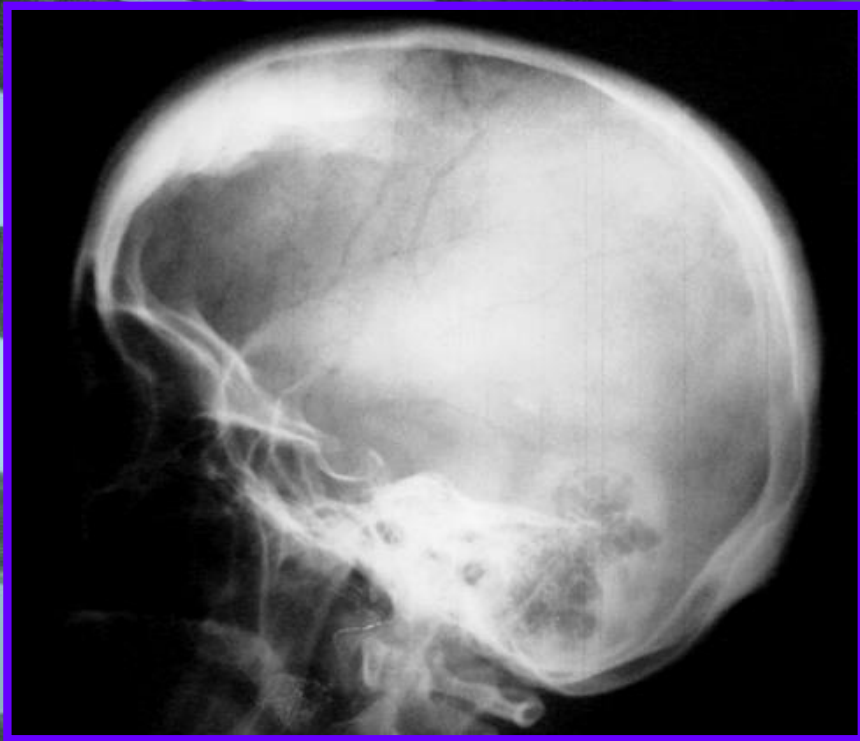
Cráneo Simple vista de Towne

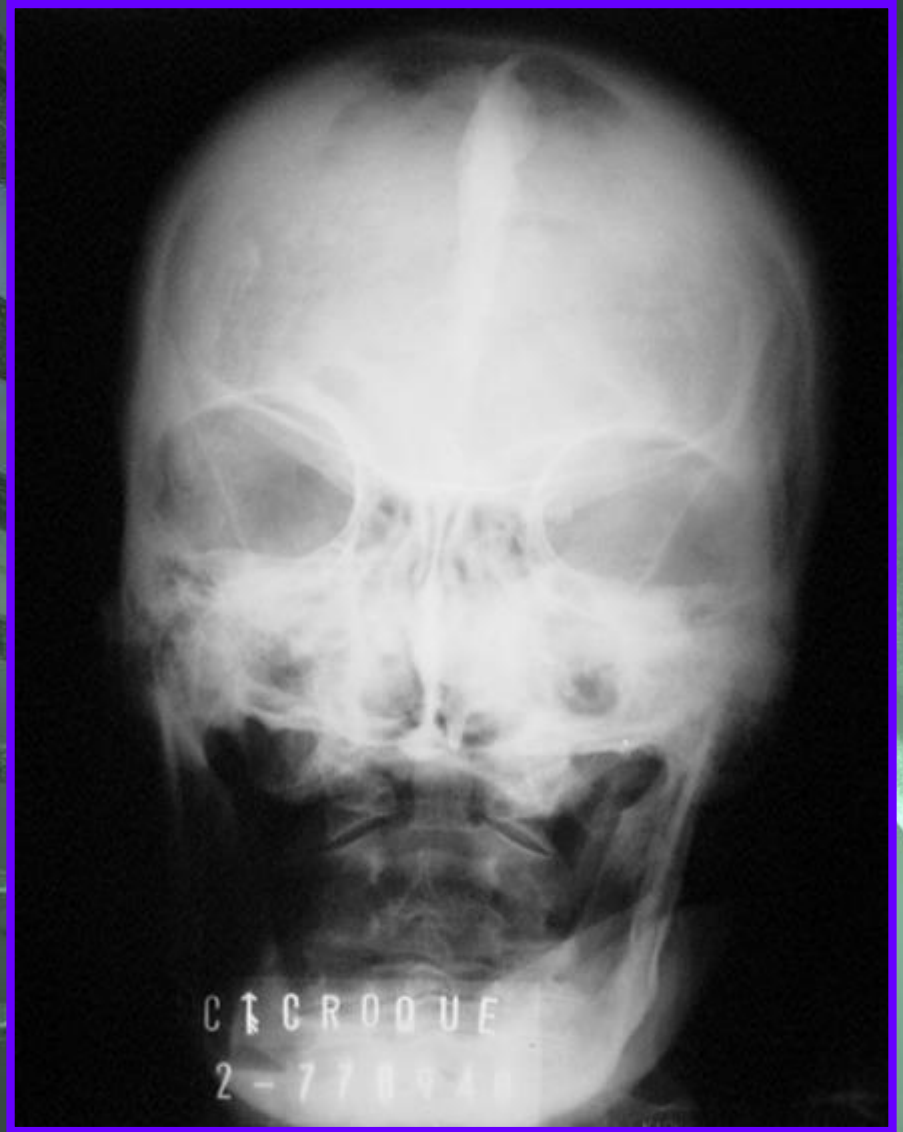
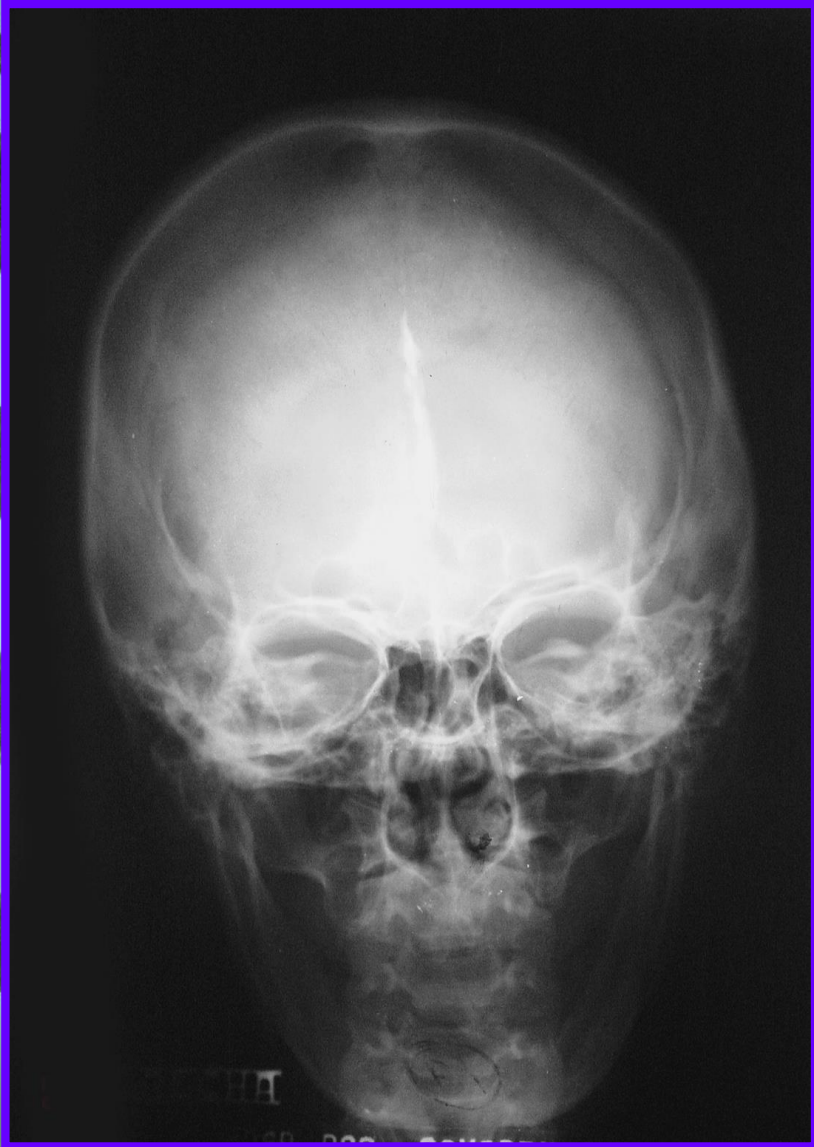
Senos Perinasales

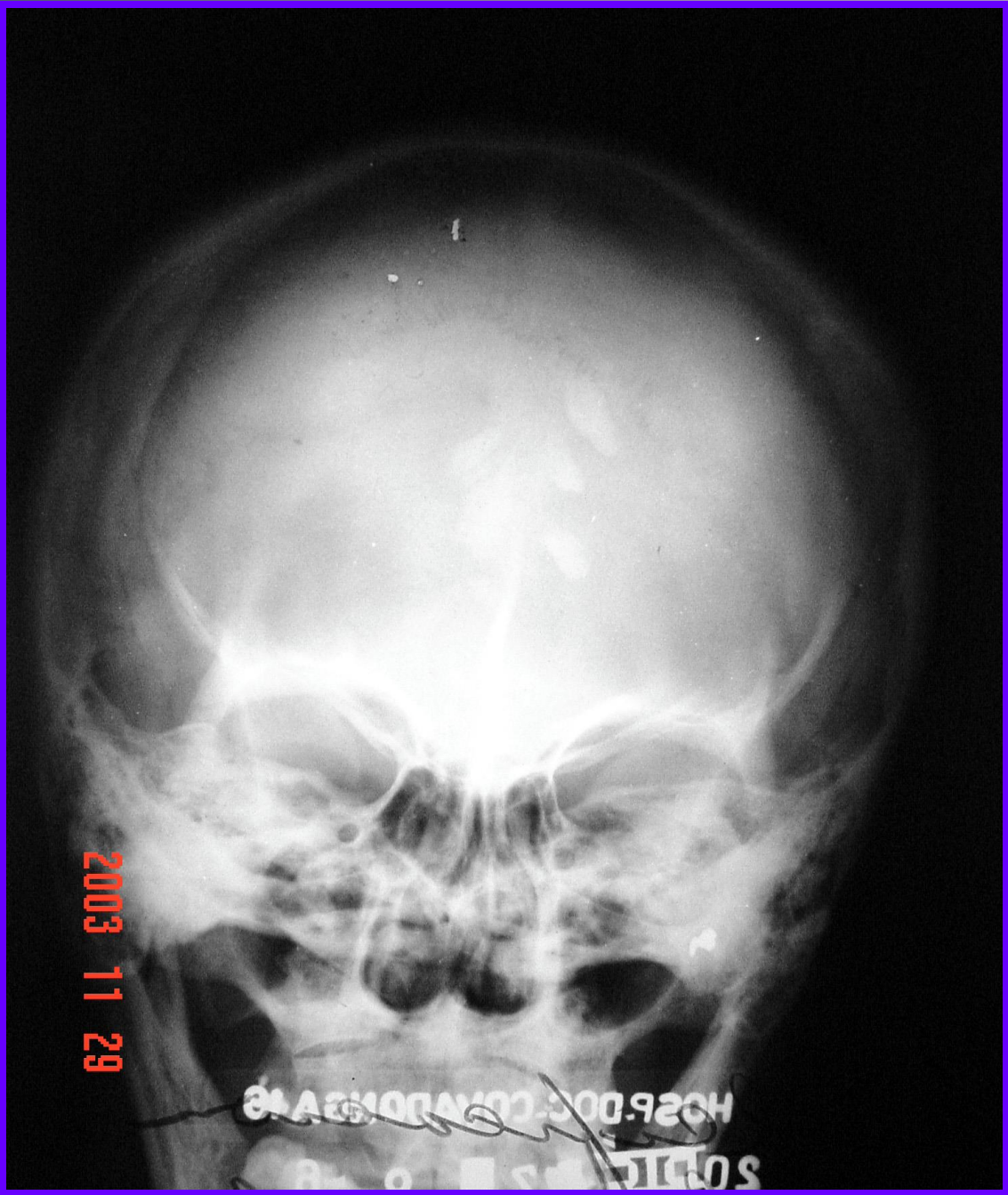

Calcificaciones Normales en el Cráneo Simple



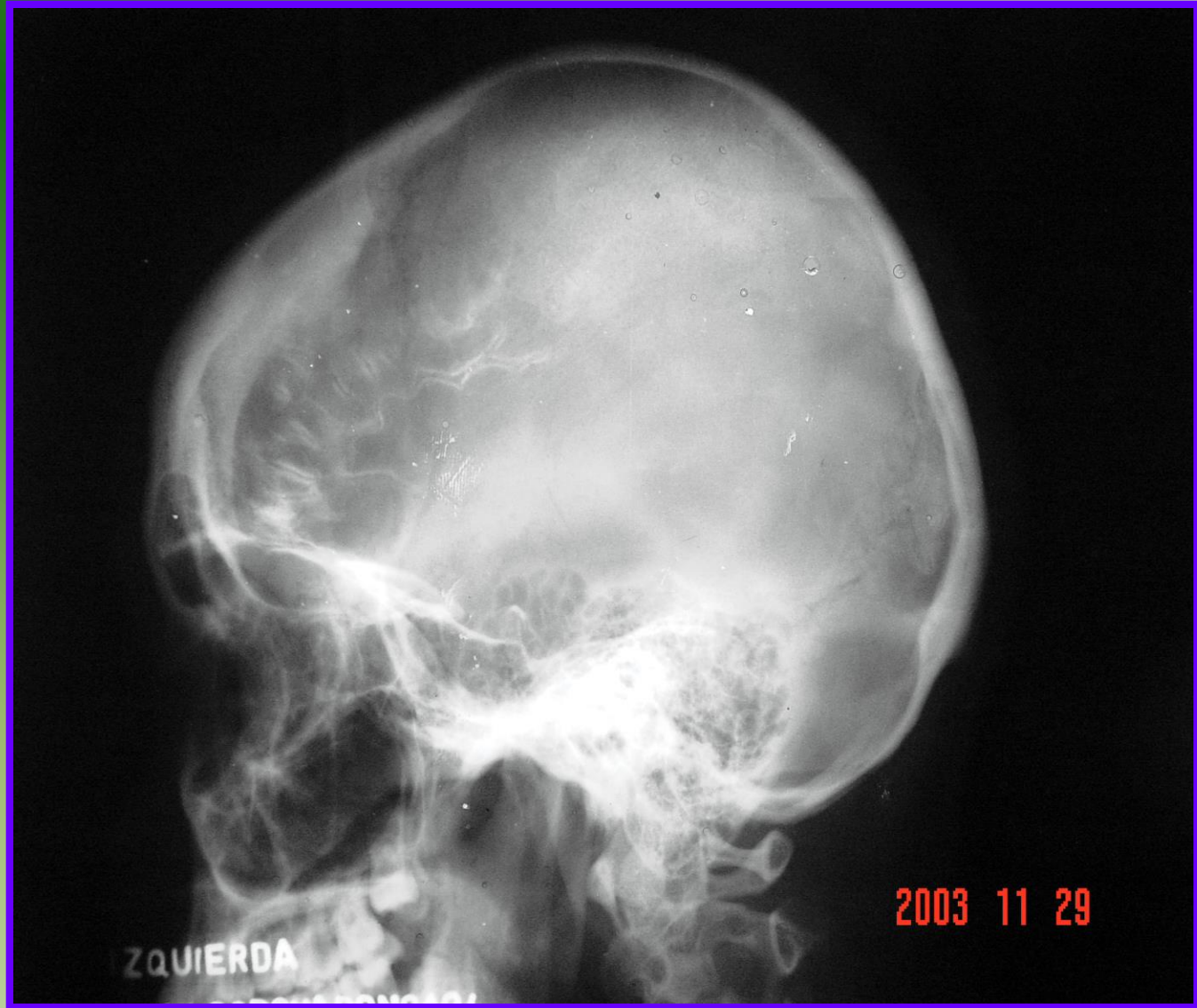

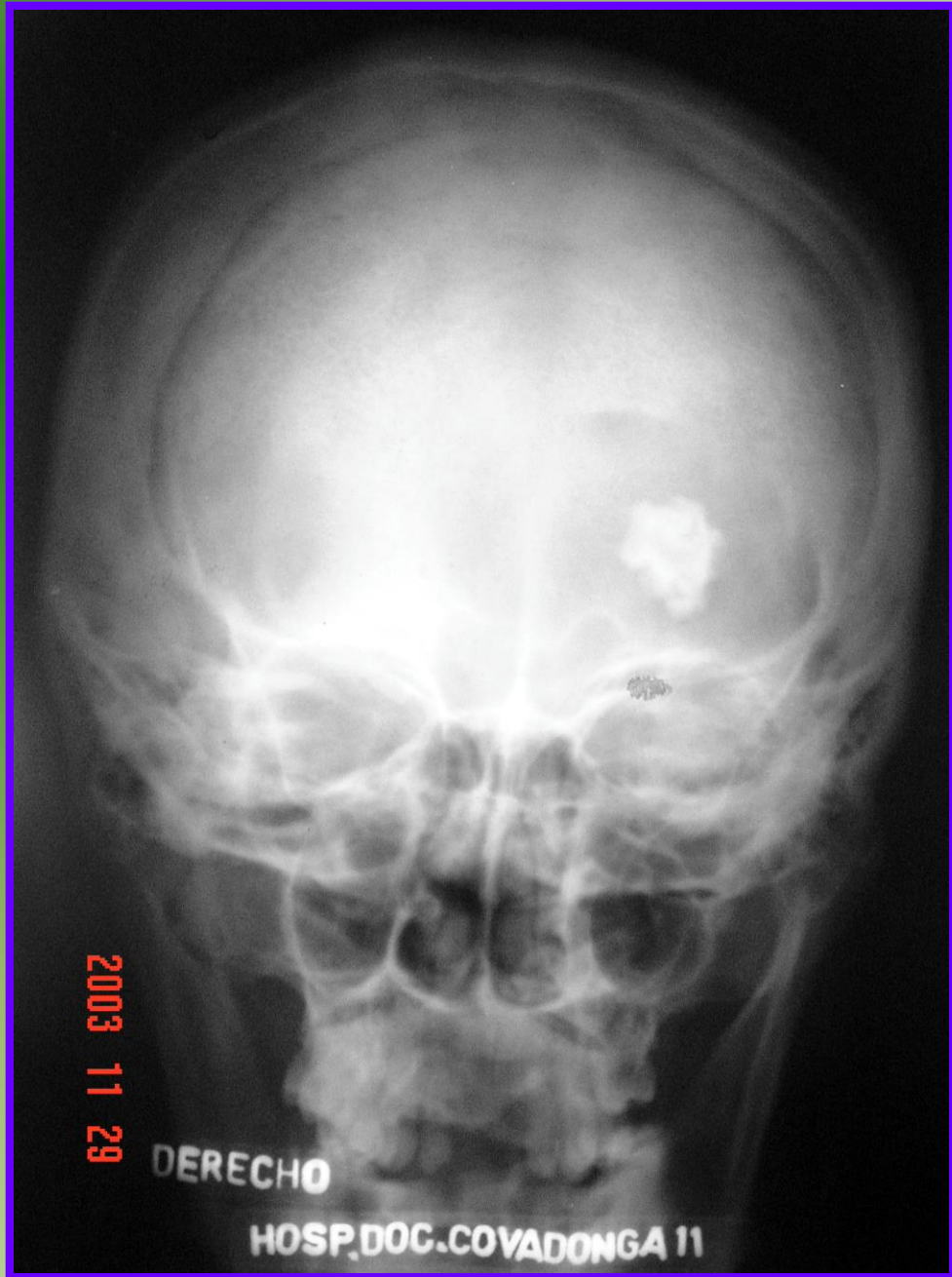Calcificaciones Patológicas en el Cráneo Simple



2003 11 29

SOE...
HOSP... COND...
Dr. O...

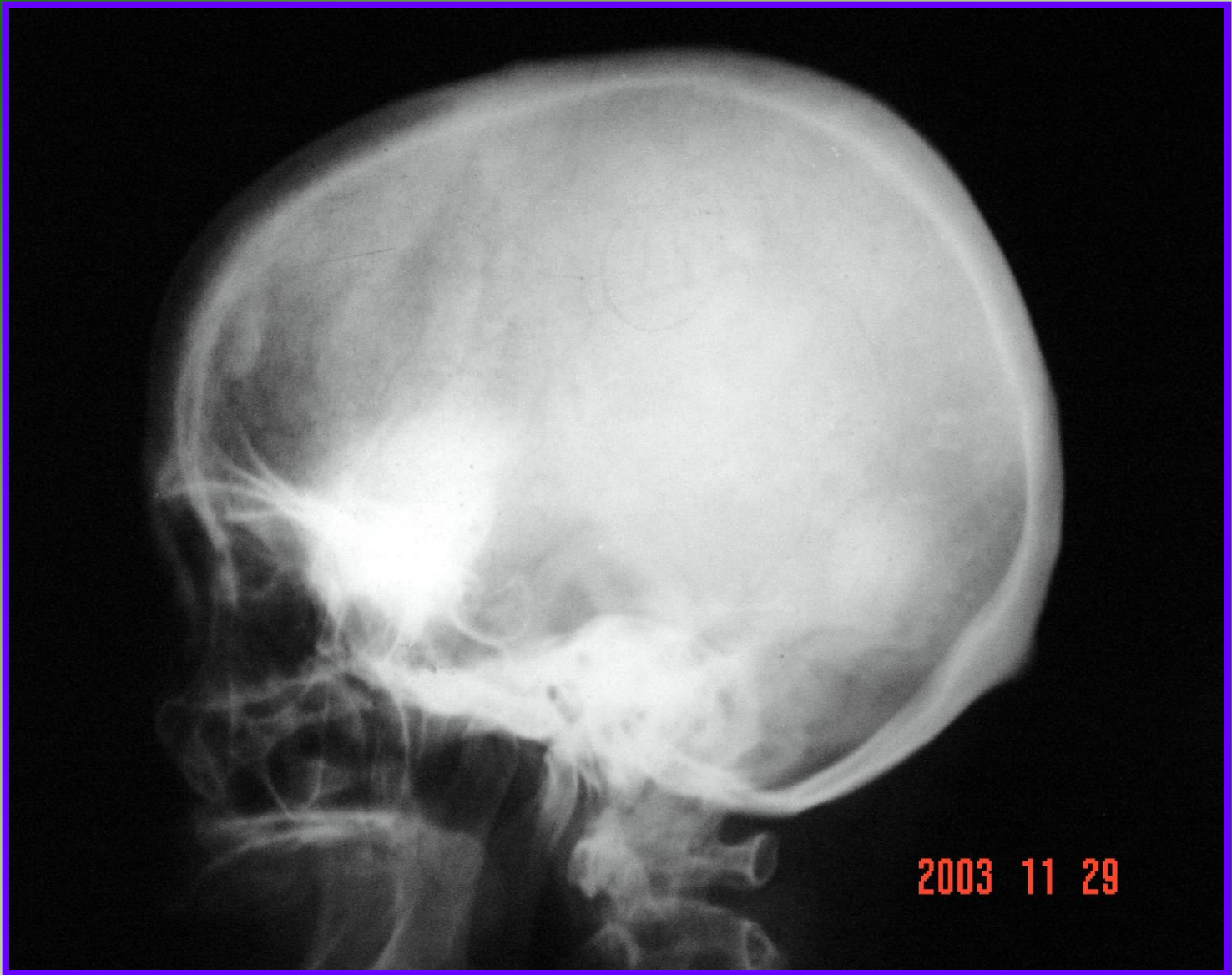




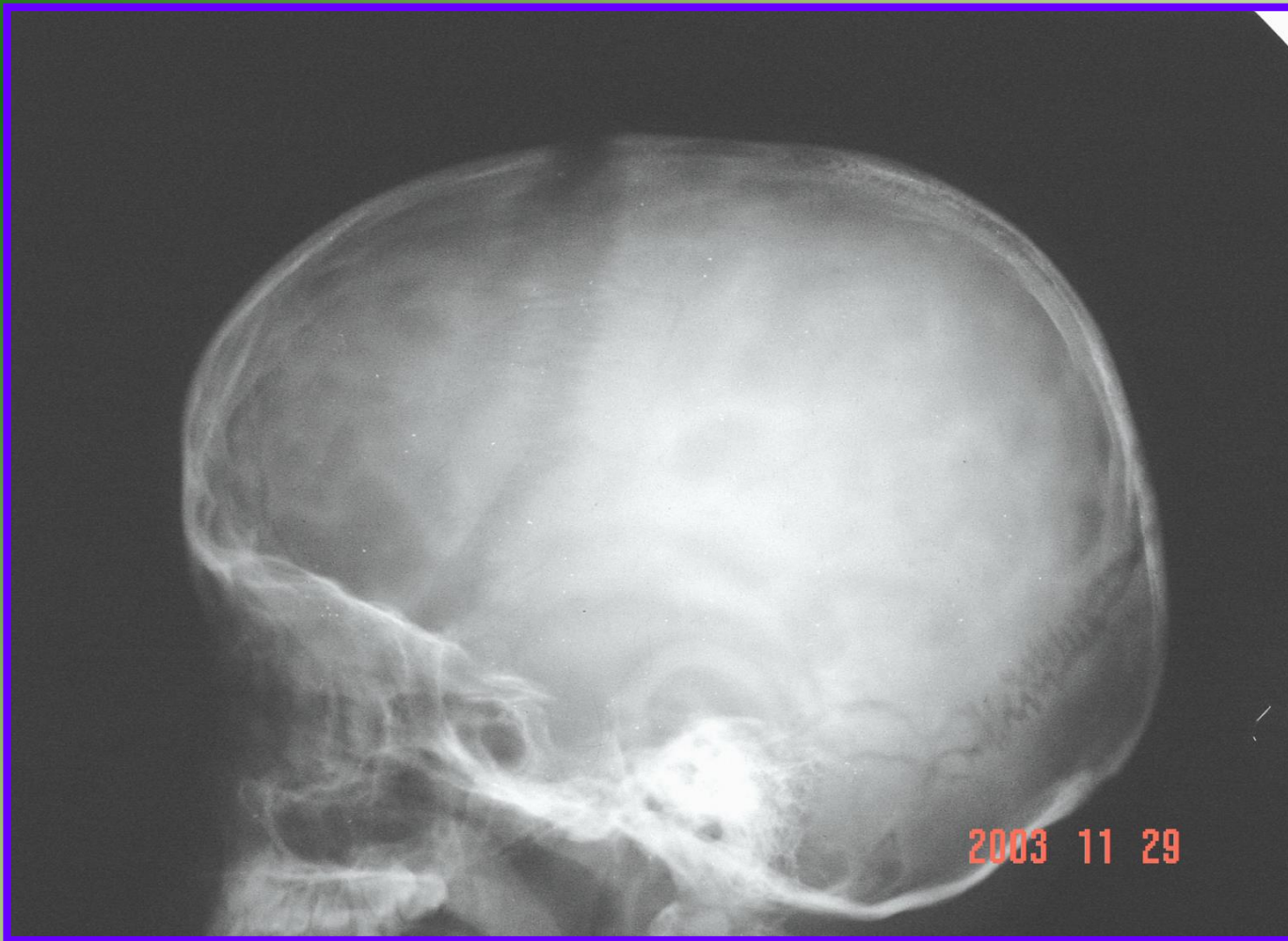
2003 11 29

DERECHO

HOSP.DOC.COYADONGA 11



Signos de Hipertensión Endocraneana



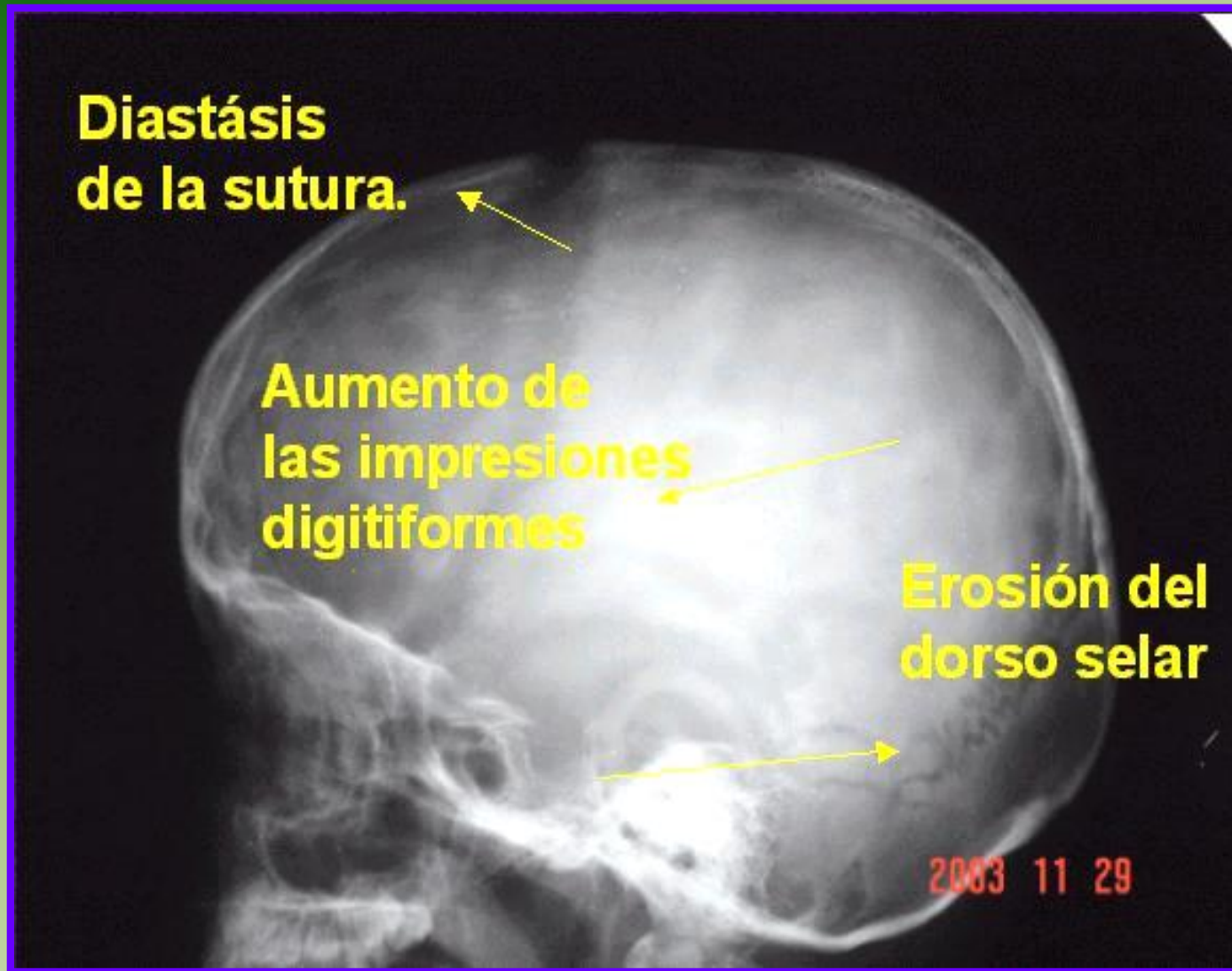**Aumento de las impresiones digitiformes
y
diastasis de las suturas**

**Diastásis
de la sutura.**

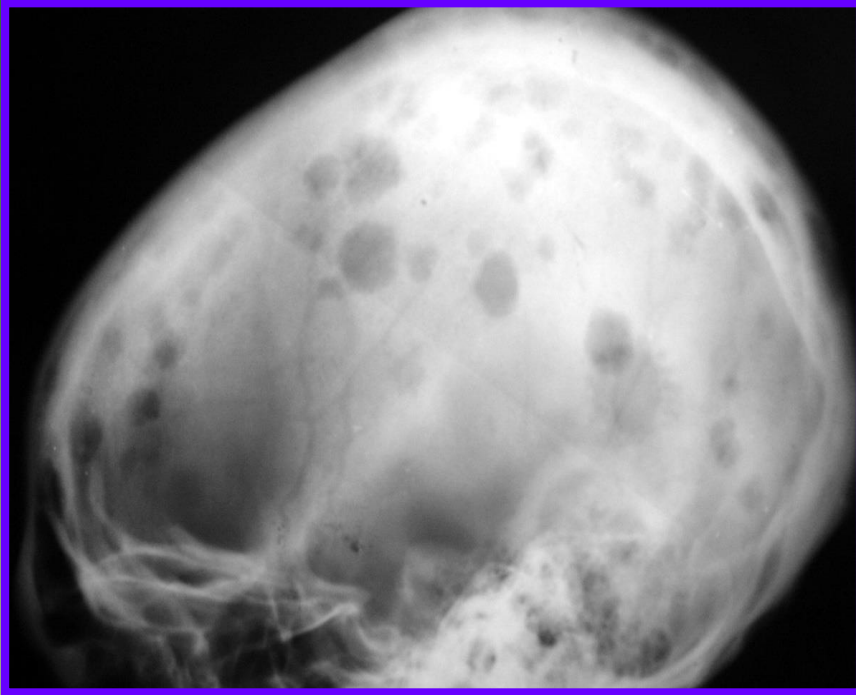
**Aumento de
las impresiones
digitiformes**

**Erosión del
dorso selar**

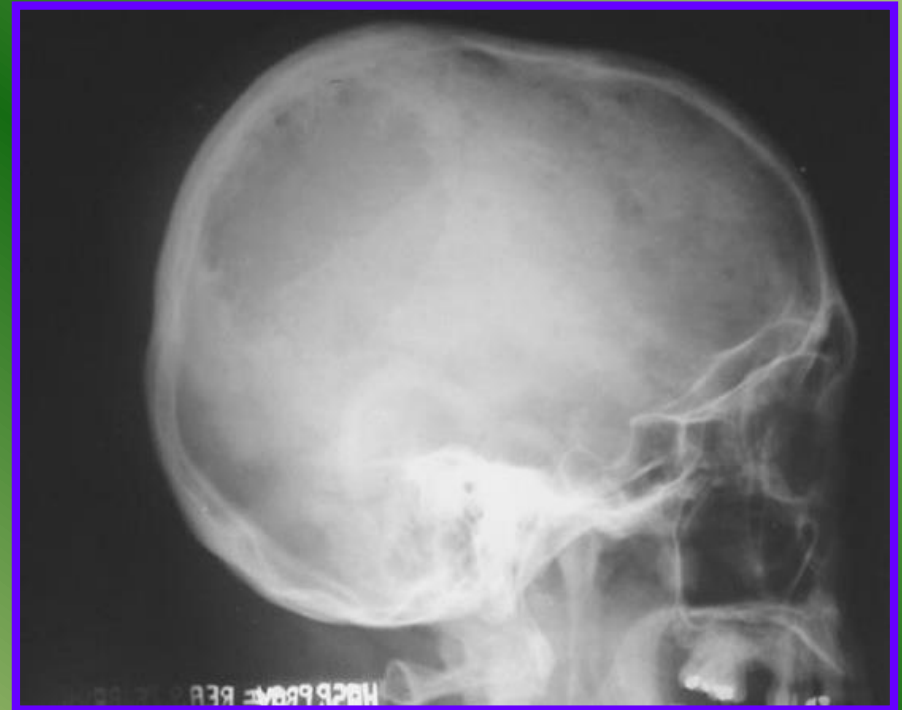2003 11 29



Lesiones Líticas en el Cráneo Simple



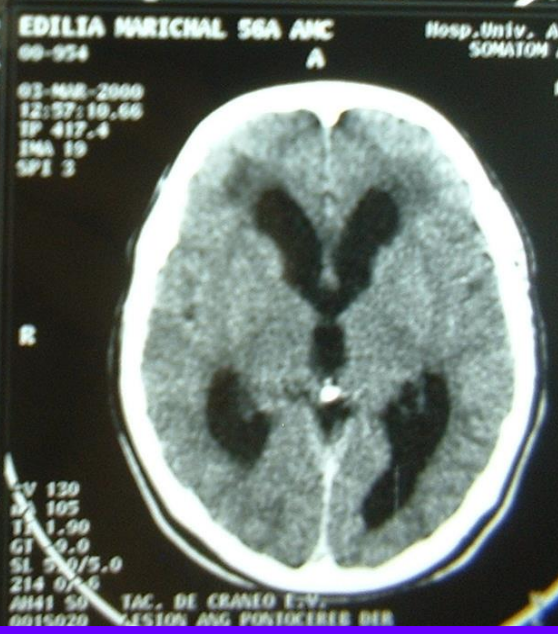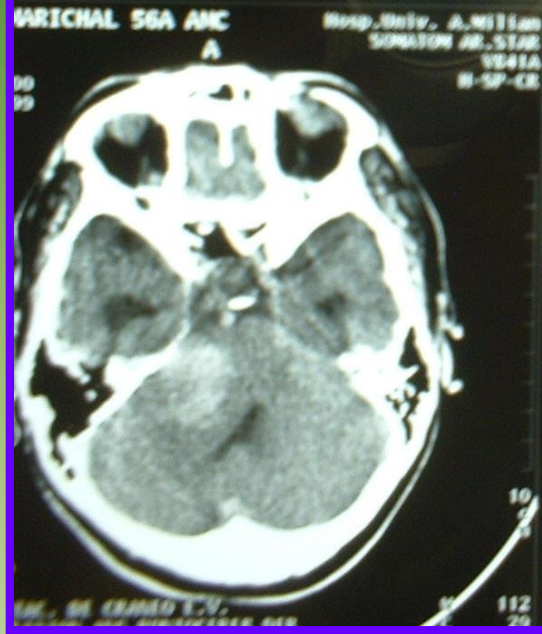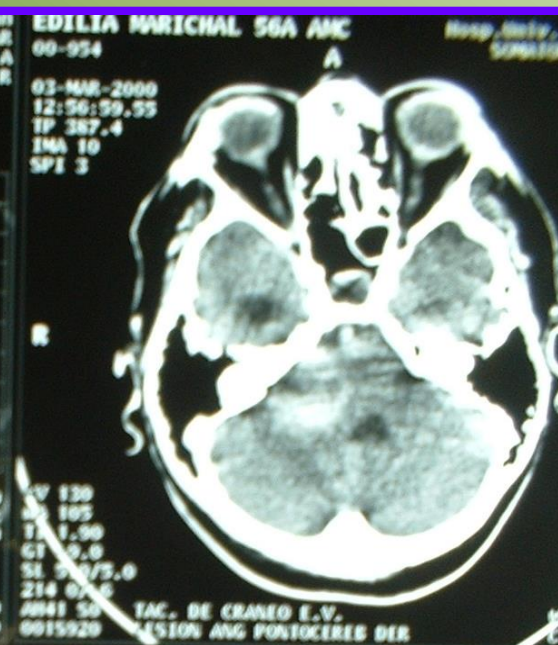
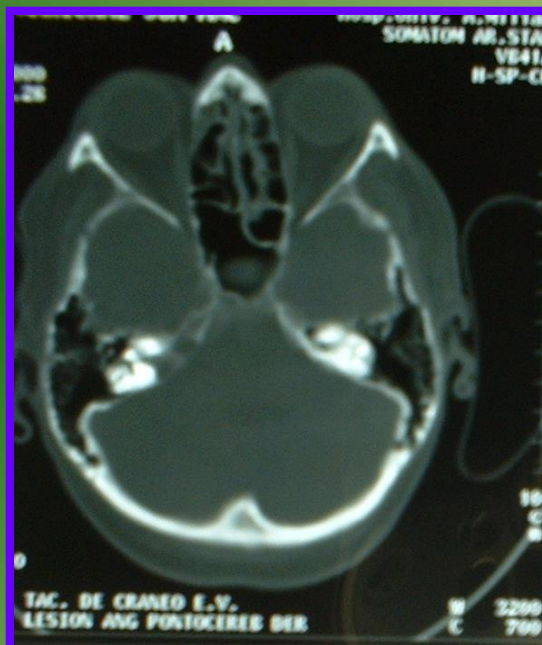
Osteolysis

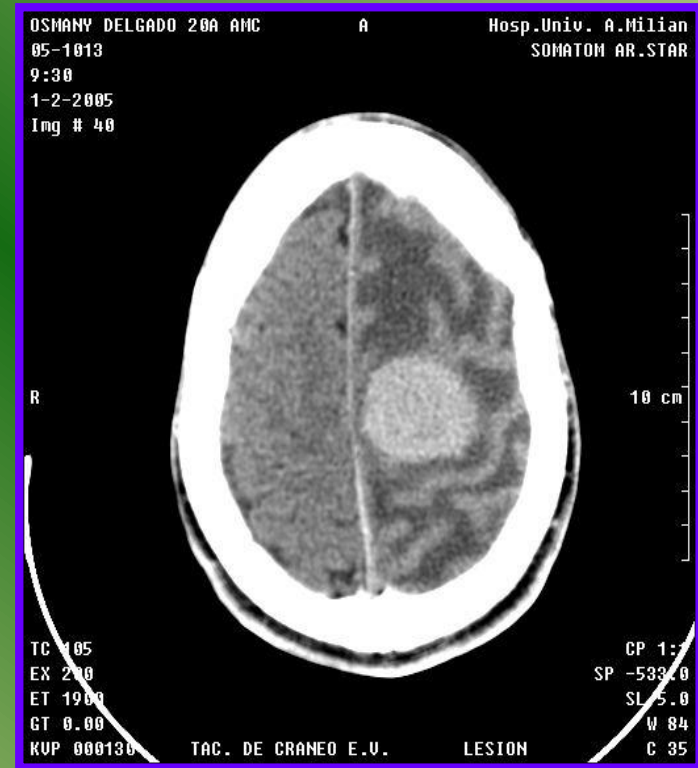
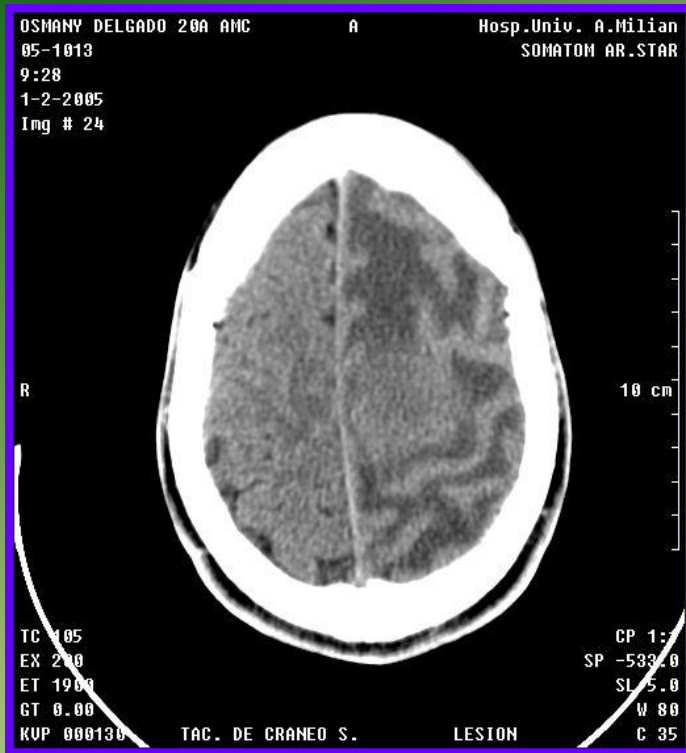

TOMOGRAFIA AXIAL COMPUTARIZADA

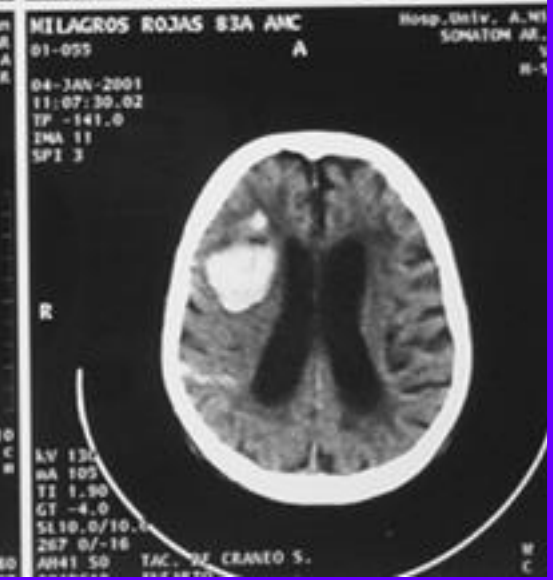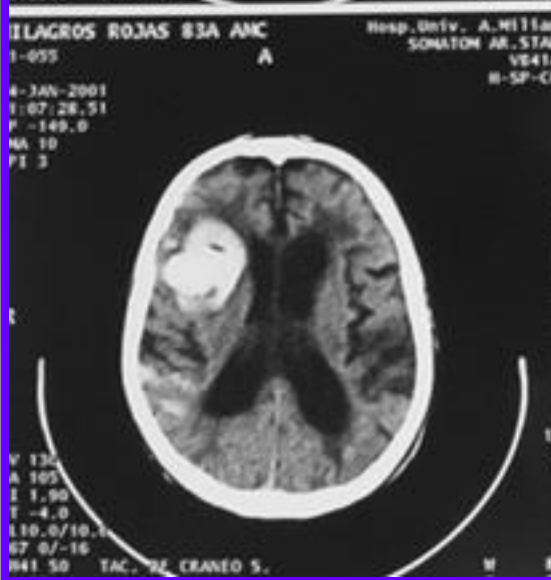
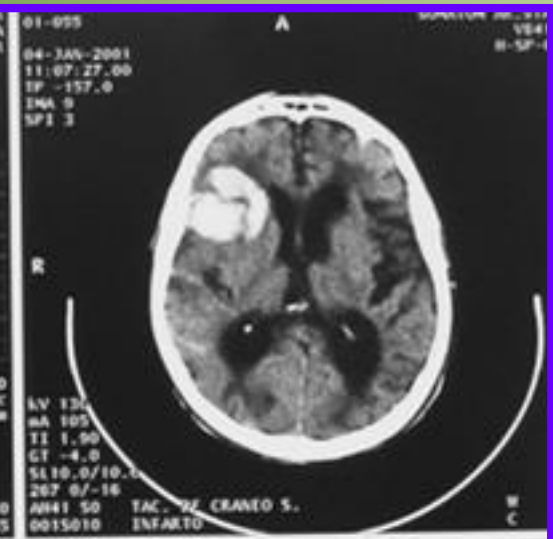
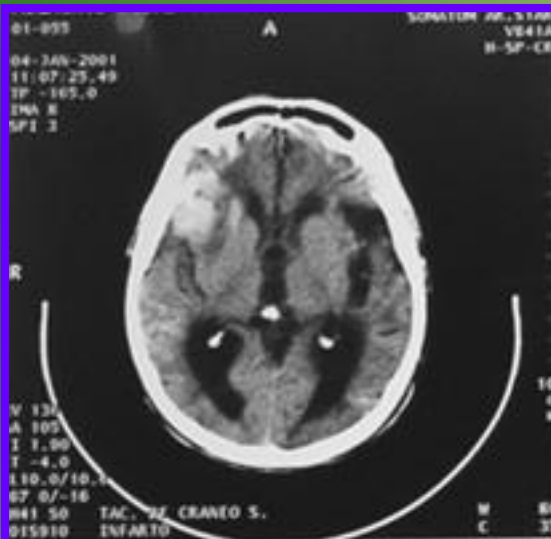


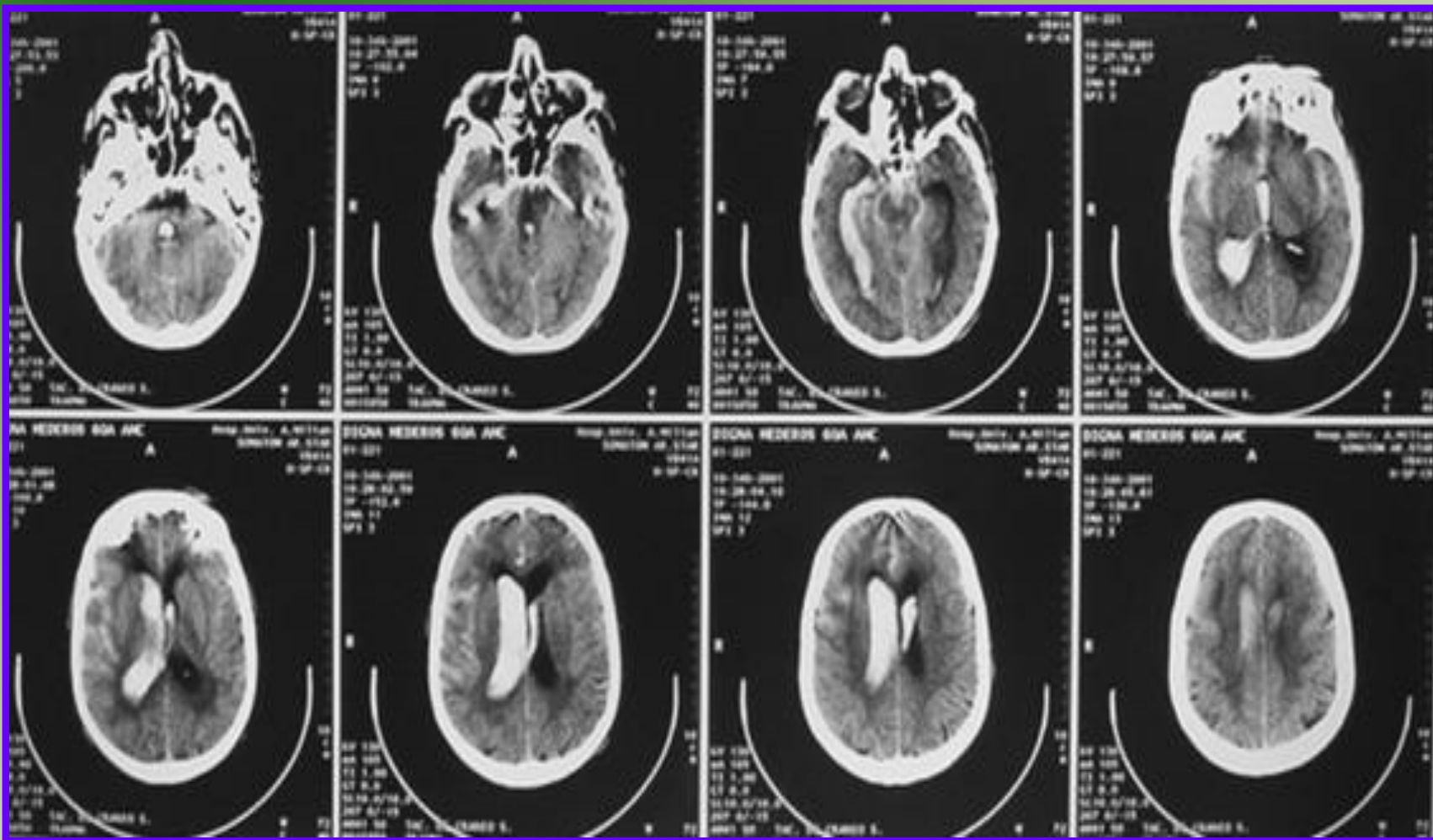
Imágenes Hiperdensas

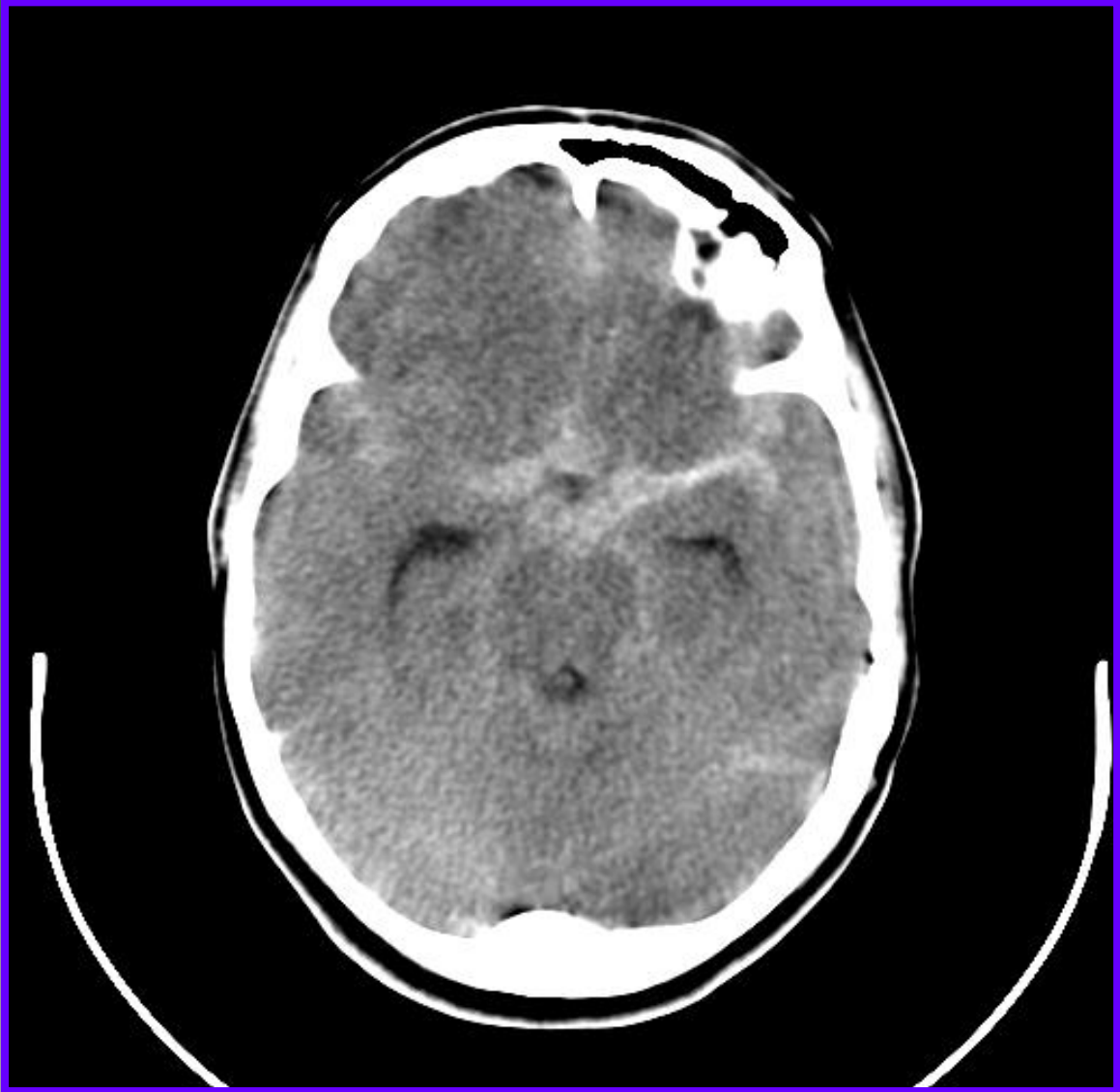


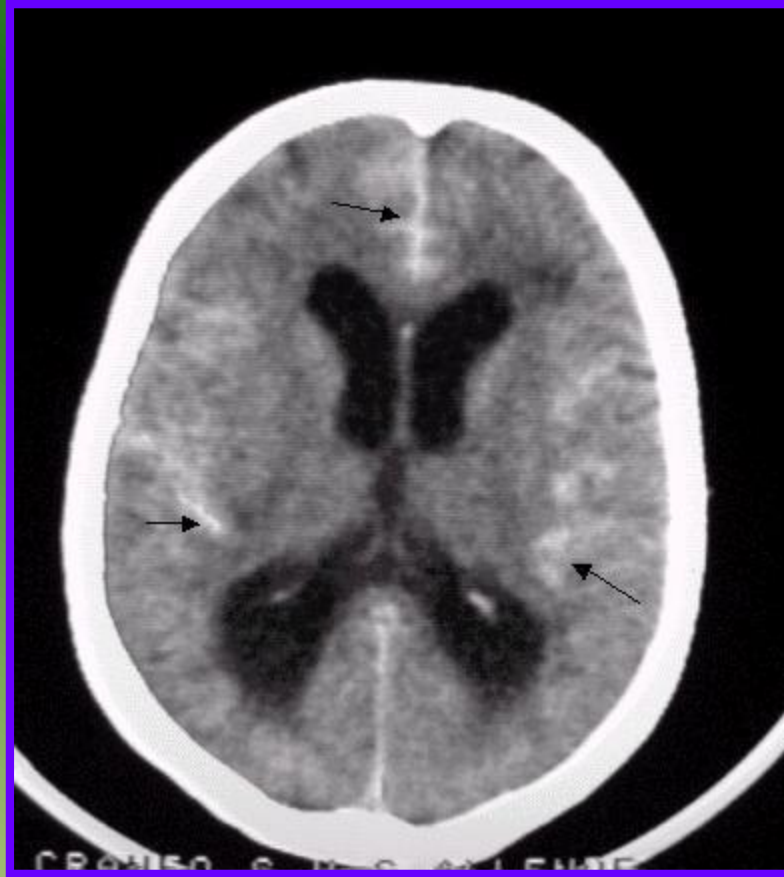

Ganancia en
densidad con la
administración de
contraste





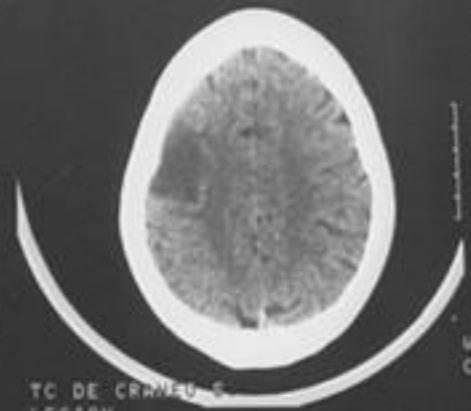
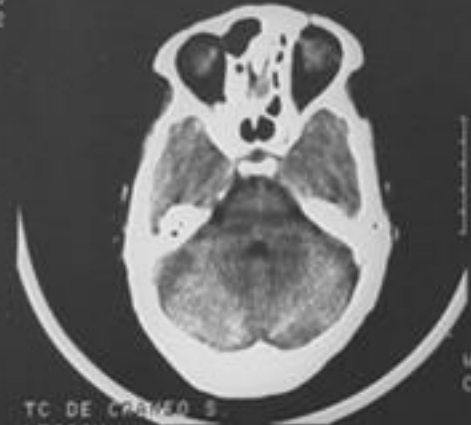




Imágenes Hipodensas

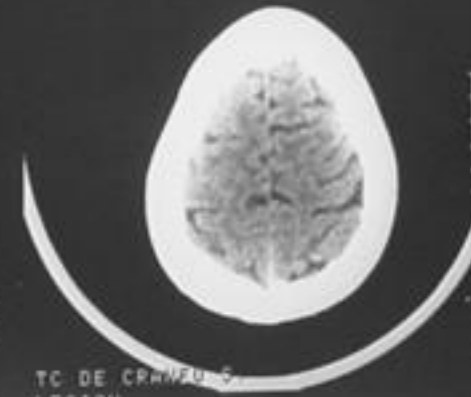
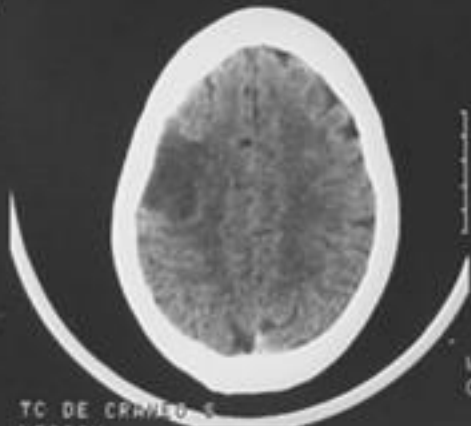
ESTHER FUENTES M54A AM 01-556
4-AUG-01 FRONT
10:29:47
DAB:111
SCAN 8

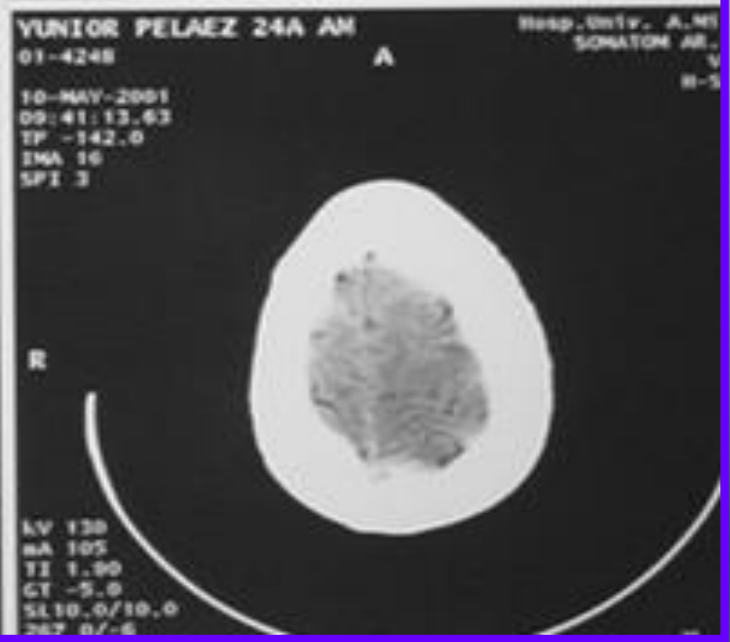
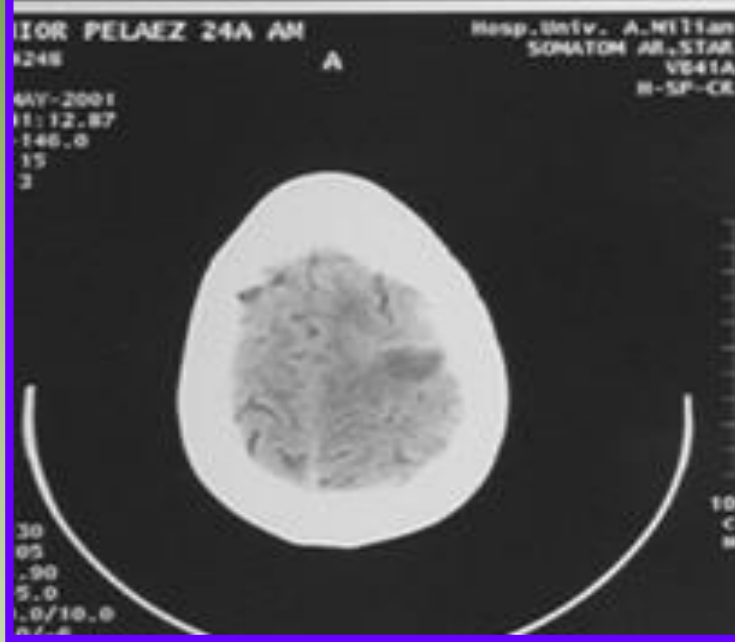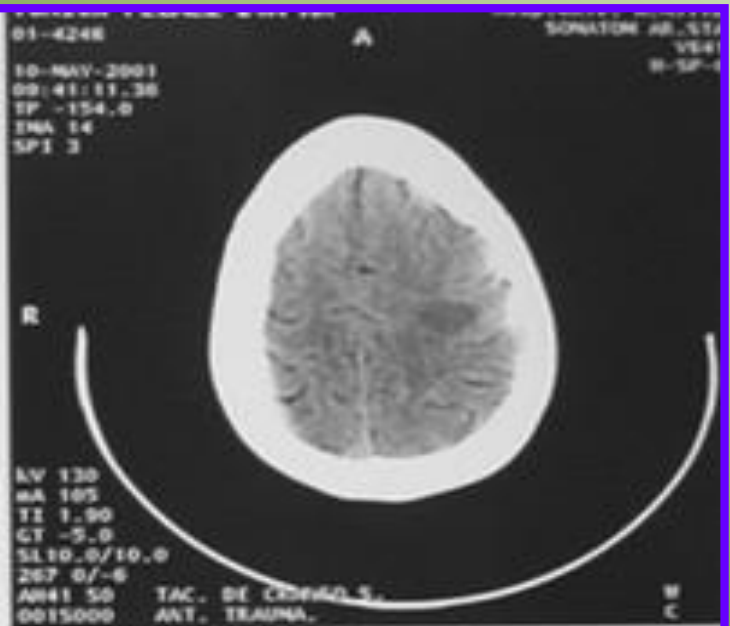
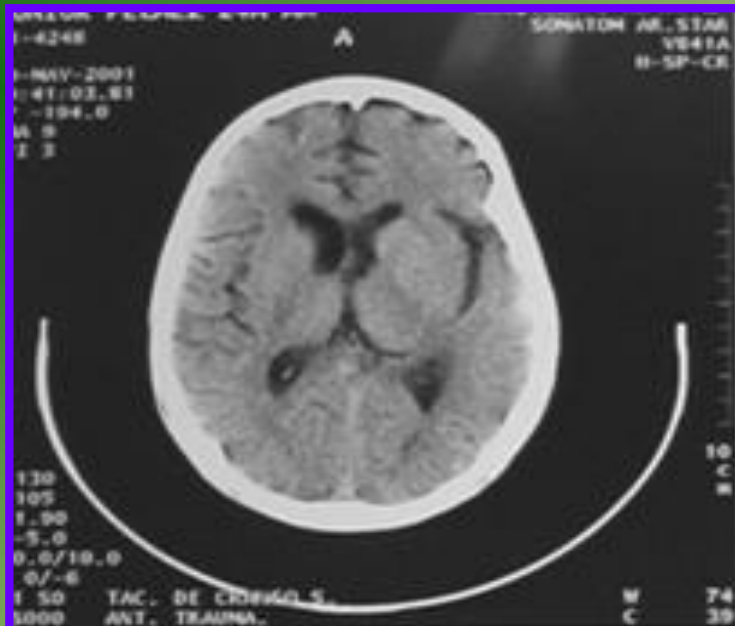
ESTHER FUENTES M54A AM 01-556
4-AUG-01 FRONT
10:32:40
DAB:114
SCAN 11



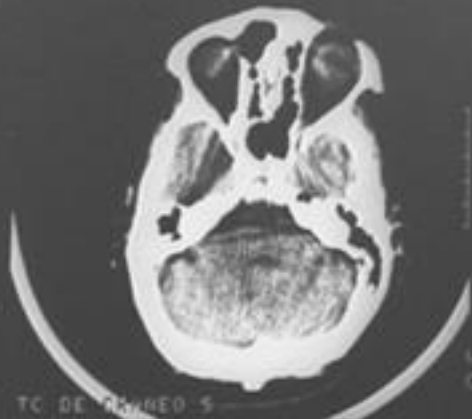
ESTHER FUENTES M54A AM 01-556
4-AUG-01 FRONT
10:31:30
DAB:112
SCAN 9

ESTHER FUENTES M54A AM 01-556
4-AUG-01 FRONT
10:32:40
DAB:114
SCAN 11



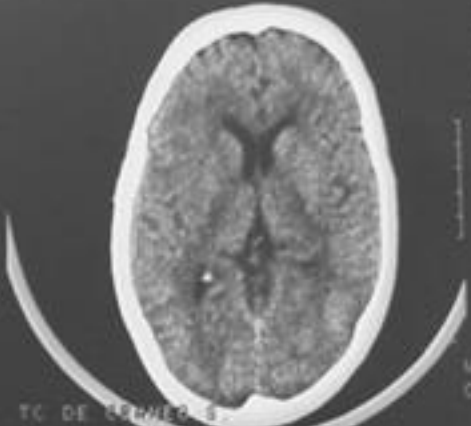


ESTHER FUENTES65A ARC 01-412
20-JUL-01 FRONT
00:31:47
DAI:012
SCAN 7

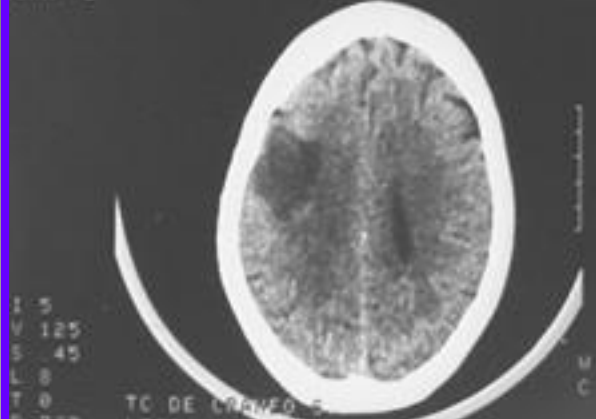


TI 5
KV 125
WS 45
SL 8
GT 0
TR 412
CORPUS LP
ESTHER FUENTES65A ARC 01-412
20-JUL-01 FRONT
00:36:42
DAI:012
SCAN 9

ESTHER FUENTES65A ARC 01-412
20-JUL-01 FRONT
00:32:43
DAI:012
SCAN 8

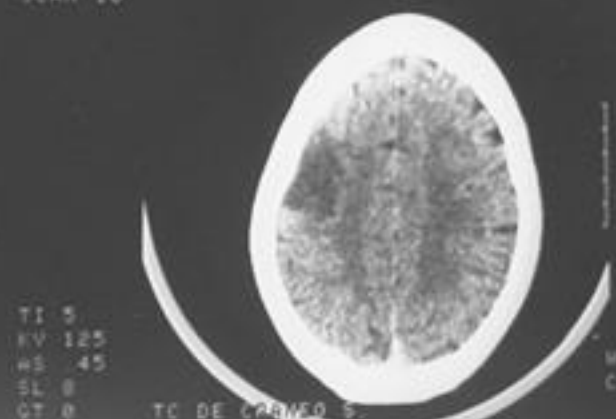


TI 5
KV 125
WS 45
SL 8
GT 0
TR 387
CORPUS LP
ESTHER FUENTES65A ARC 01-412
20-JUL-01 FRONT
00:37:30
DAI:012
SCAN 10



TI 5
KV 125
WS 45
SL 8
GT 0
TR 367

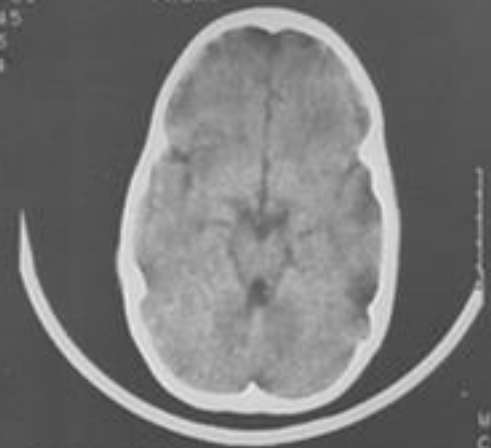
R I G H T
S C N
M 00
C 37



TI 5
KV 125
WS 45
SL 8
GT 0
TR 384

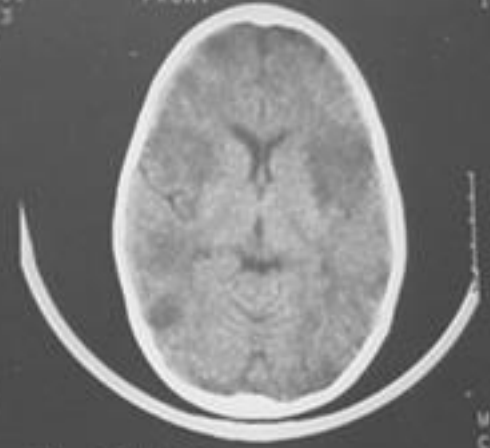
R I G H T
S C N
M 00
C 37

ETSER PEREZ 3A H. I. 01-883 OC2
5-SEP-01 FRONT 1.66B
09:23:45 H/SP
DAI: 045
SCAN 4



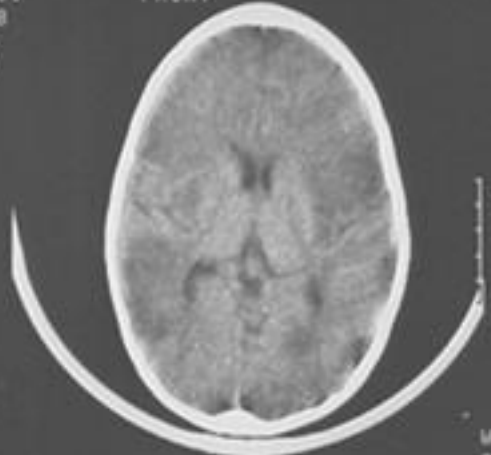
R
I
G
H
T
5 CM
TI 5
KV 125
AS .45
SL 8
GT 12 TC. CRANEO S.
TP. 450 EVOLUTIVO
M 80
C 7

ETSER PEREZ 3A H. I. 01-883 OC2
5-SEP-01 FRONT 1.66B
09:24:53 H/SP
DAI: 047
SCAN 6



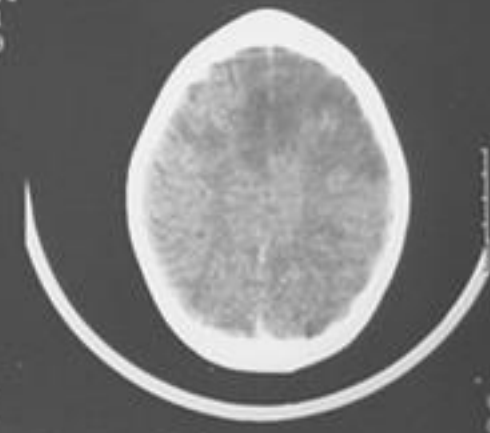
R
I
G
H
T
5 CM
TI 5
KV 125
AS .45
SL 8
GT 12 TC. CRANEO S.
TP. 434 EVOLUTIVO
M 80
C 7

SURATOR LK HUSP. "ARMANDO RILIAN" V.C.
ETSER PEREZ 3A H. I. 01-883 OC2
5-SEP-01 FRONT 1.66B
09:25:28 H/SP
DAI: 048
SCAN 7



R
I
G
H
T
5 CM
TI 5
KV 125
AS .45
SL 8
GT 12 TC. CRANEO S.
M 80
C 7

SURATOR LK HUSP. "ARMANDO RILIAN" V.C.
ETSER PEREZ 3A H. I. 01-883 OC2
5-SEP-01 FRONT 1.66B
09:27:13 H/SP
DAI: 051
SCAN 10



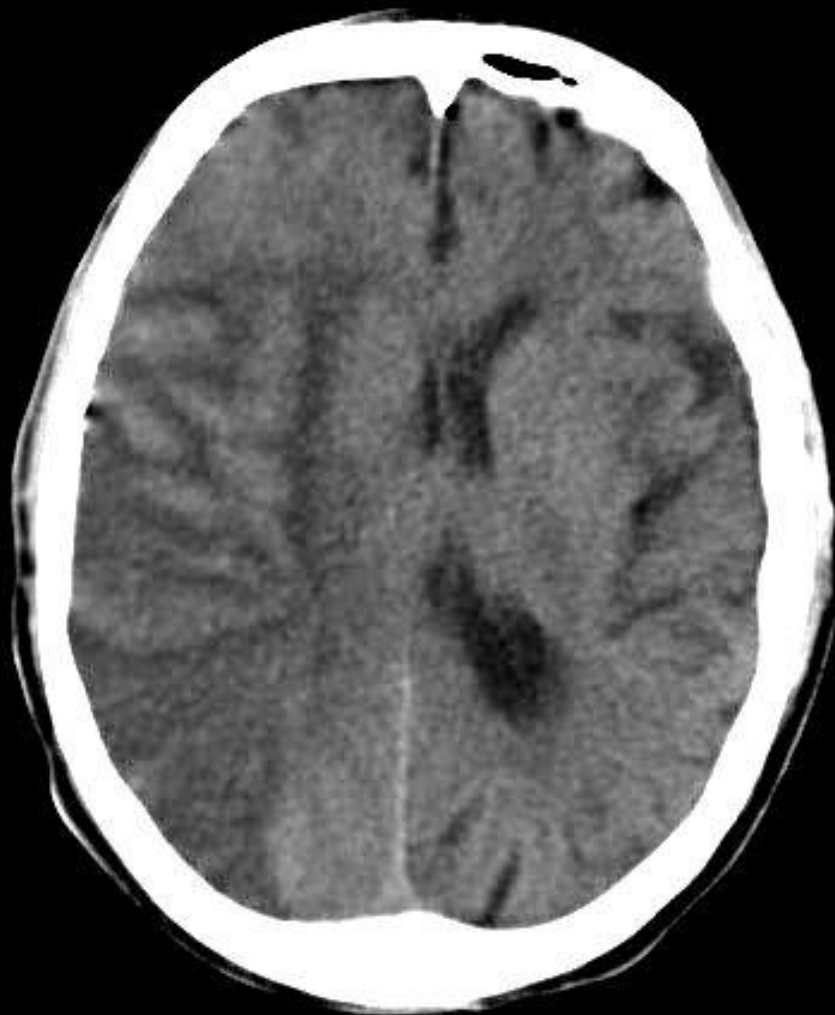R
I
G
H
T
5 CM
TI 5
KV 125
AS .45
SL 8
GT 12 TC. CRANEO S.
M 80
C 8

ROLANDO CRESPO 65A C.H
05-710
9:35
24-1-2005
Img # 11

AH

Hosp.Univ. A.Milian
SOMATOM AR.STAR

R



10 cm

TC 105
EX 200
ET 1900
GT -19.00
KUP 000100

TAC. DE CRANEO S.

LESION CERB.

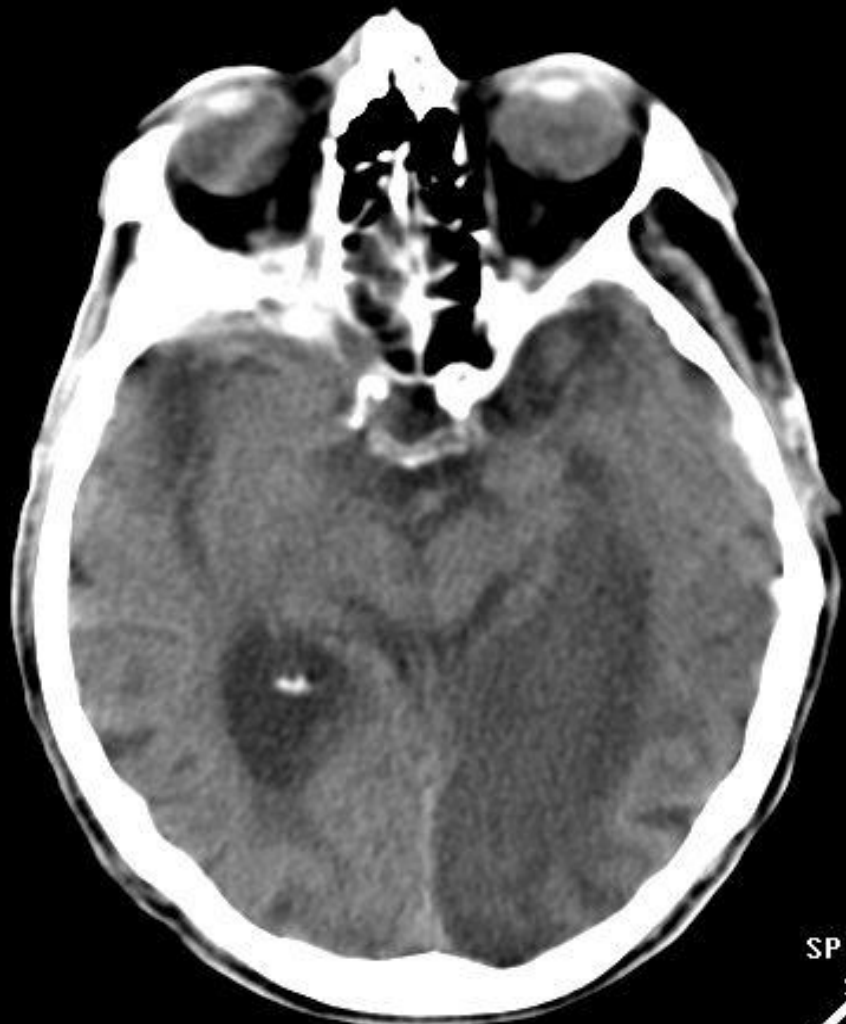CP 1:1
SP -524.0
SL 10.0
W 80
C 35

GERARDO PEREZ 85A AMC
05-968
10:4
31-1-2005
Img # 8

A

Hosp.Univ. A.Milian
SOMATOM AR.STAR

R



10 cm

TC 105
EX 200
ET 1900
GT 0.00
KUP 000130

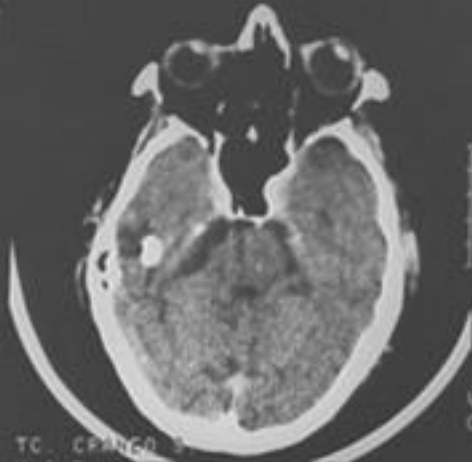
TAC. DE CRANEO S.

LESION

CP 1:1
SP -574.0
SL 10.0
W 111
C 35

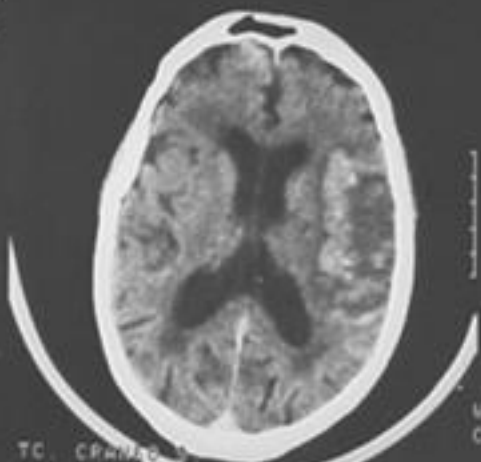
Imágenes Hiperdensas e Hipodensas

ANTONIO REYES 77A AM 01-817
30-AUG-81 FRONT
08-30-47
DAI:022
SCAN 2



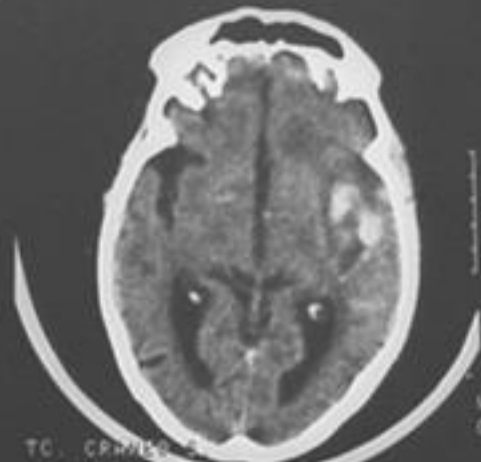
TI 5
KV 125
AS 45
SL 0
GT 0 TC CRANIO
TP 411 H I P

SUNSHINE LN
ANTONIO REYES 77A AM 01-817
30-AUG-81 FRONT
08-33-30
DAI:026
SCAN 6



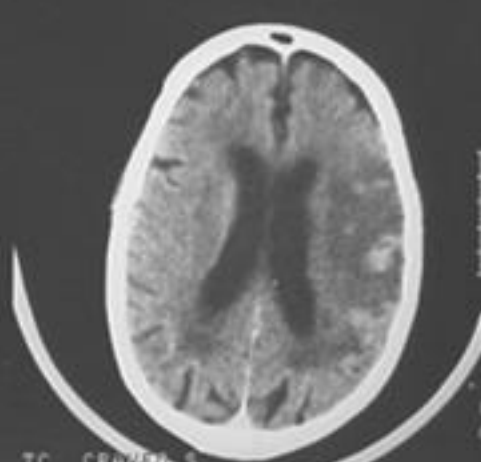
TI 5
KV 125
AS 45
SL 0
GT 0 TC CRANIO
TP 375 H I P

ANTONIO REYES 77A AM 01-817
30-AUG-81 FRONT
08-32-49
DAI:025
SCAN 5



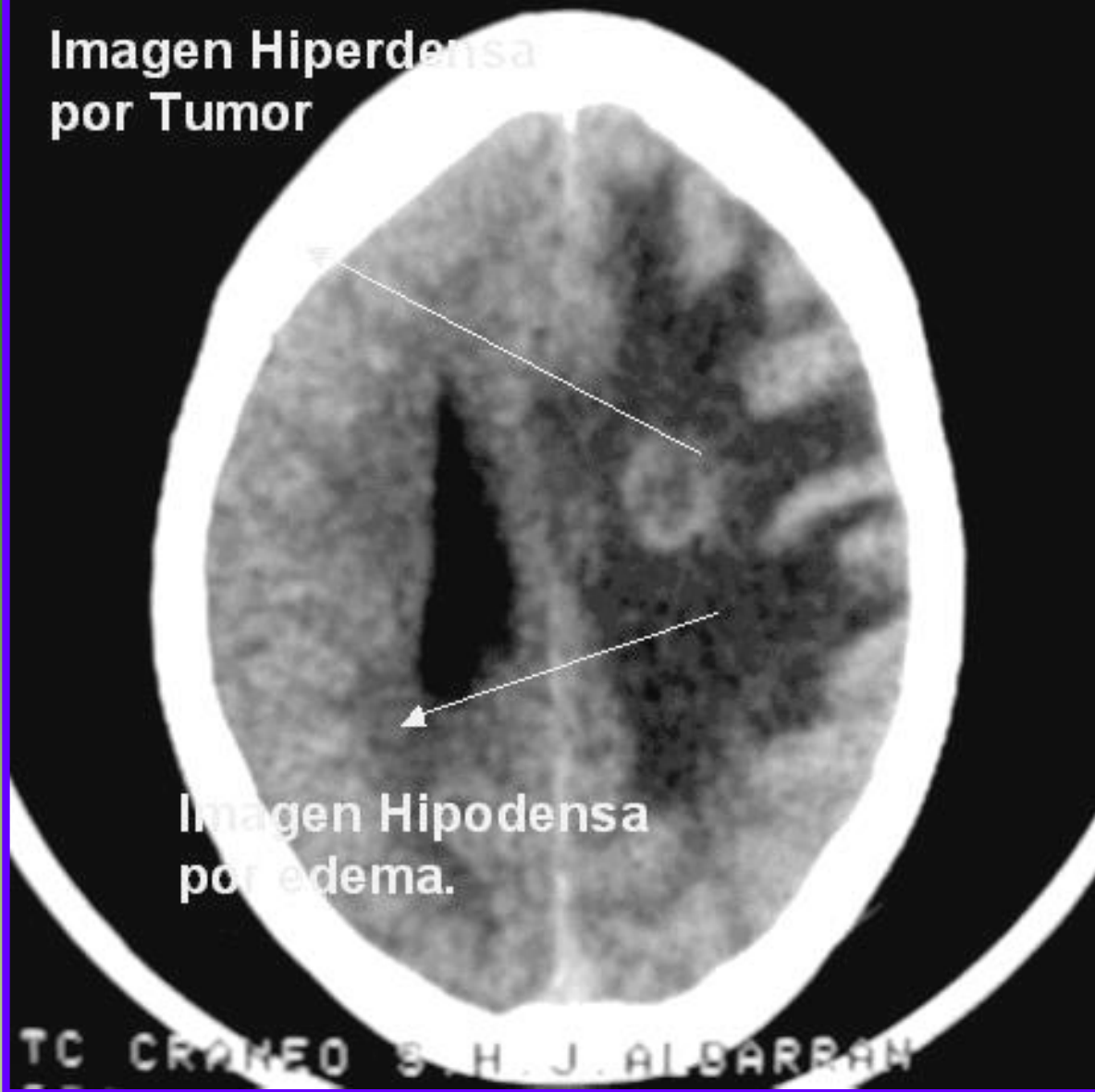
TI 5
KV 125
AS 45
SL 0
GT 0 TC CRANIO
TP 391 H I P

SUNSHINE LN
ANTONIO REYES 77A AM 01-817
30-AUG-81 FRONT
08-34-04
DAI:027
SCAN 7



TI 5
KV 125
AS 45
SL 0
GT 0 TC CRANIO

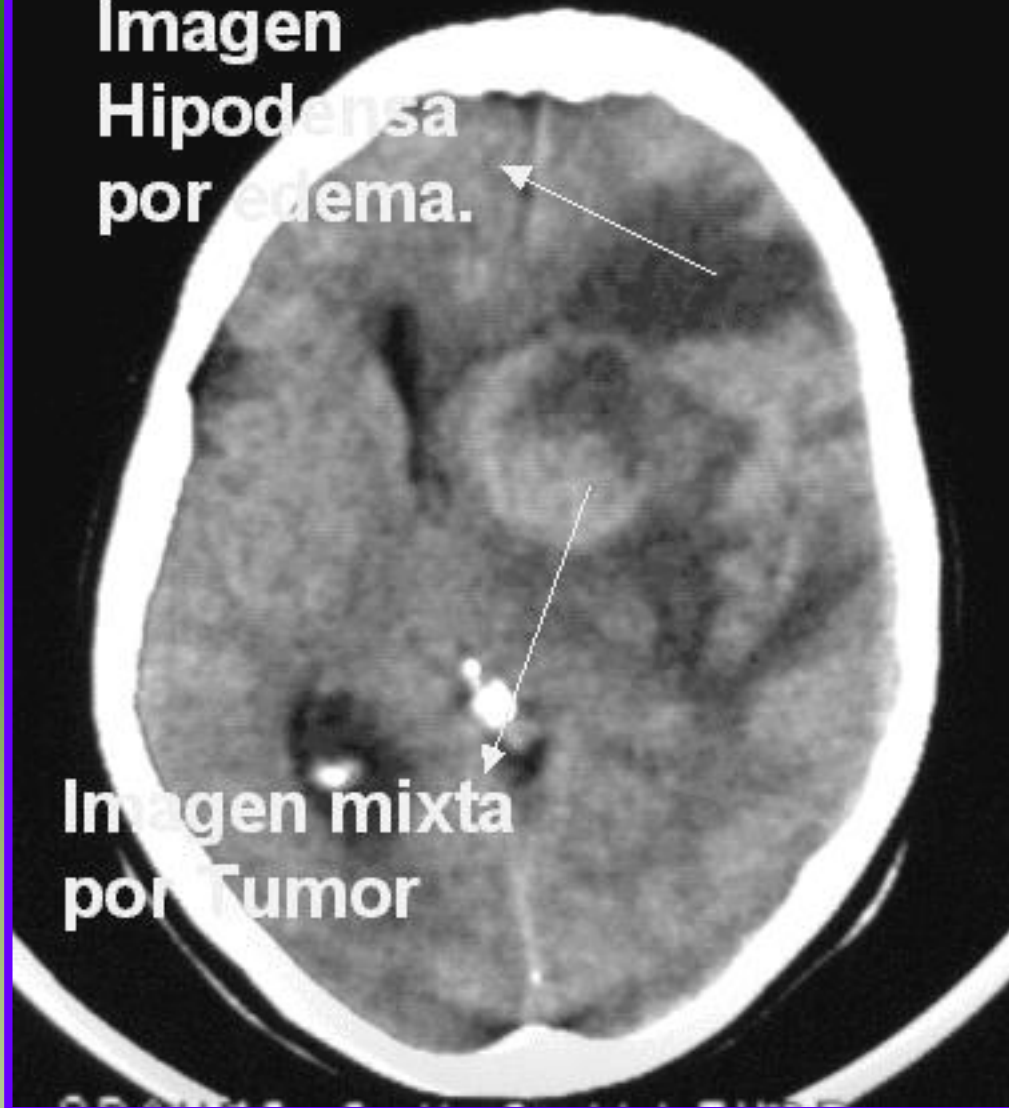**Imagen Hiperdensa
por Tumor**



**Imagen Hipodensa
por edema.**

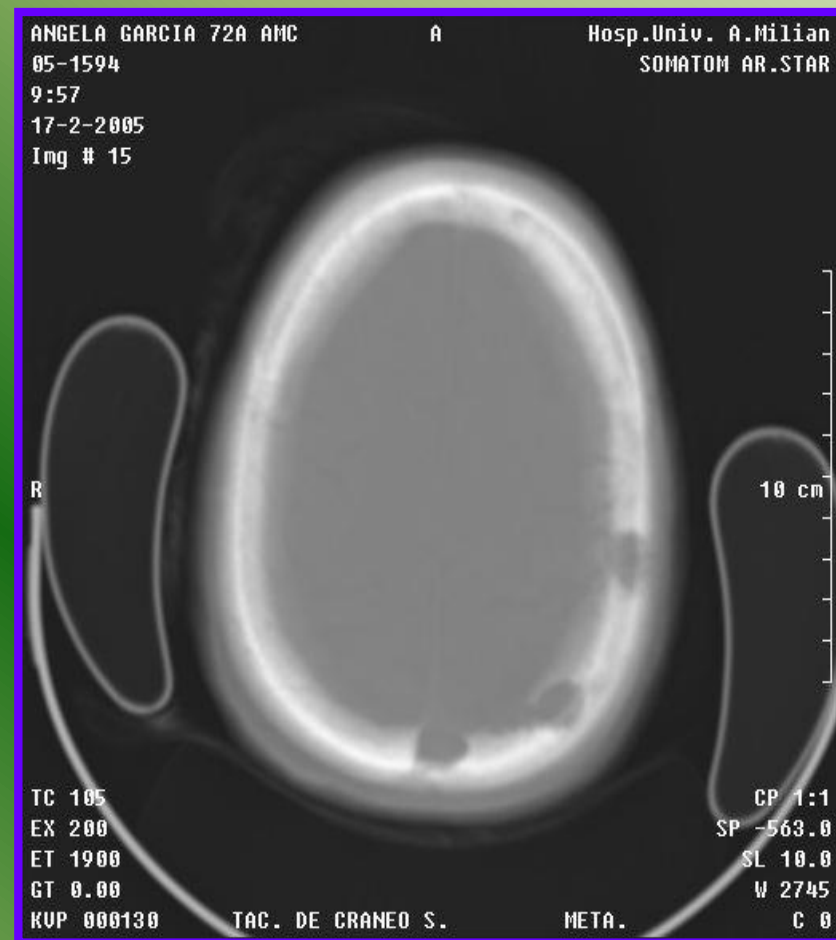
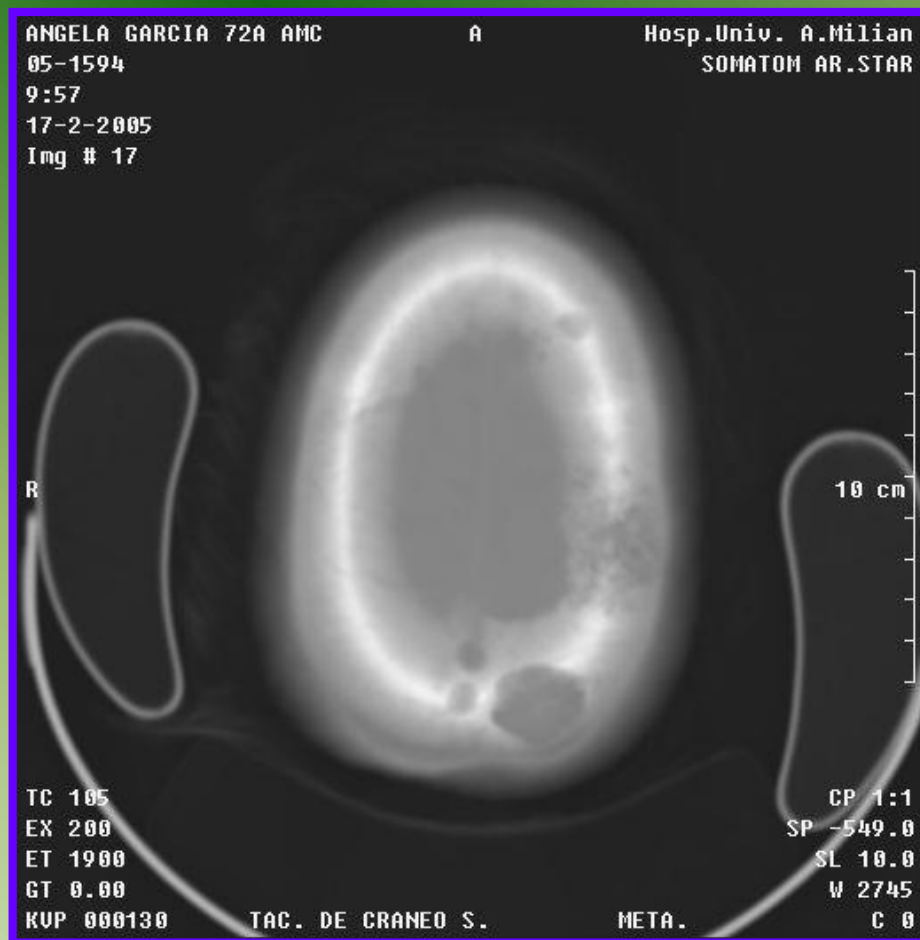TC CRANEO S. H. J. ALBARRAN

**Imagen
Hipodensa
por edema.**



**Imagen mixta
por Tumor**

Lesiones Líticas en TAC



Lesiones líticas con ventana ósea