

# Sistema Nervioso

# Sumario:

- Indicación del estudio imagenológico para los síndromes del sistema nervioso.
- Anatomía radiográfica del cráneo. Sistemática del estudio de cráneo simple.
- TAC Simple de cráneo: Definición de imágenes hipodensas e hiperdensas.
- Imagenología en el estudio de los síndromes del sistema nervioso: Hipertensión endocraneana, Meníngeo, Convulsivo, Hemipléjico, Cefalea.

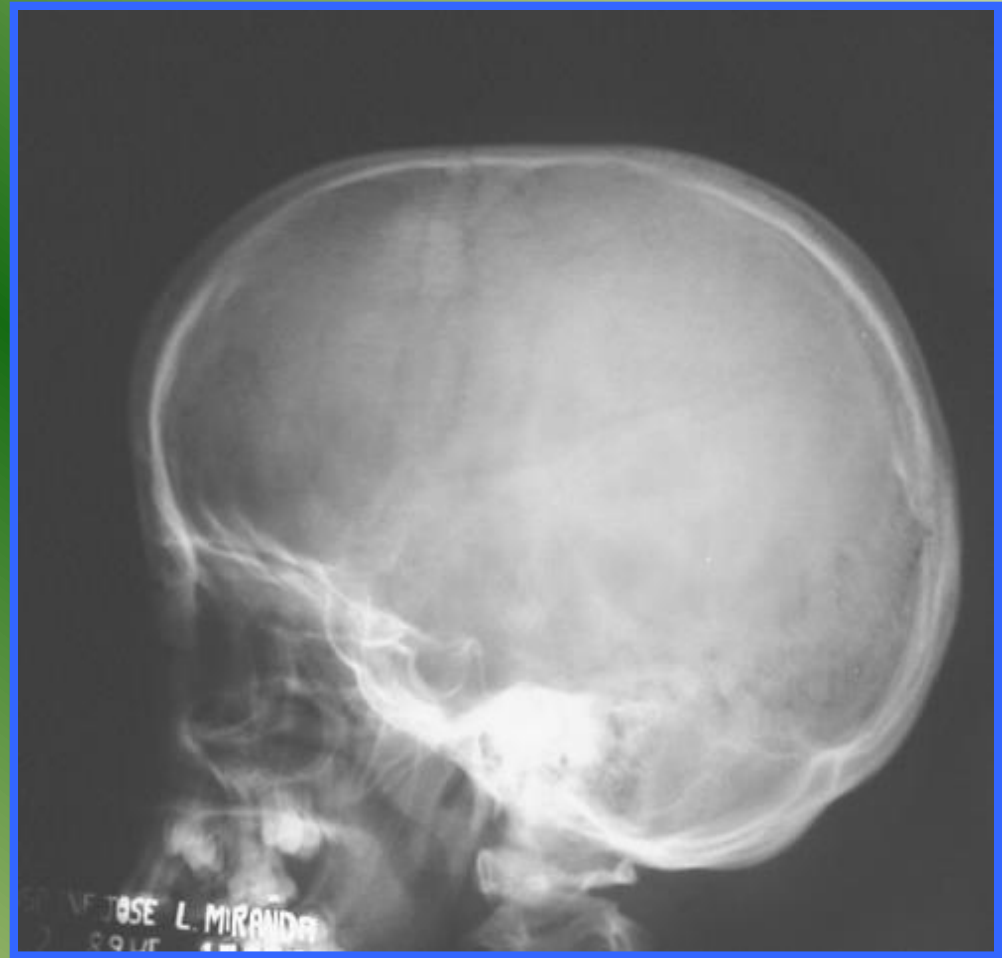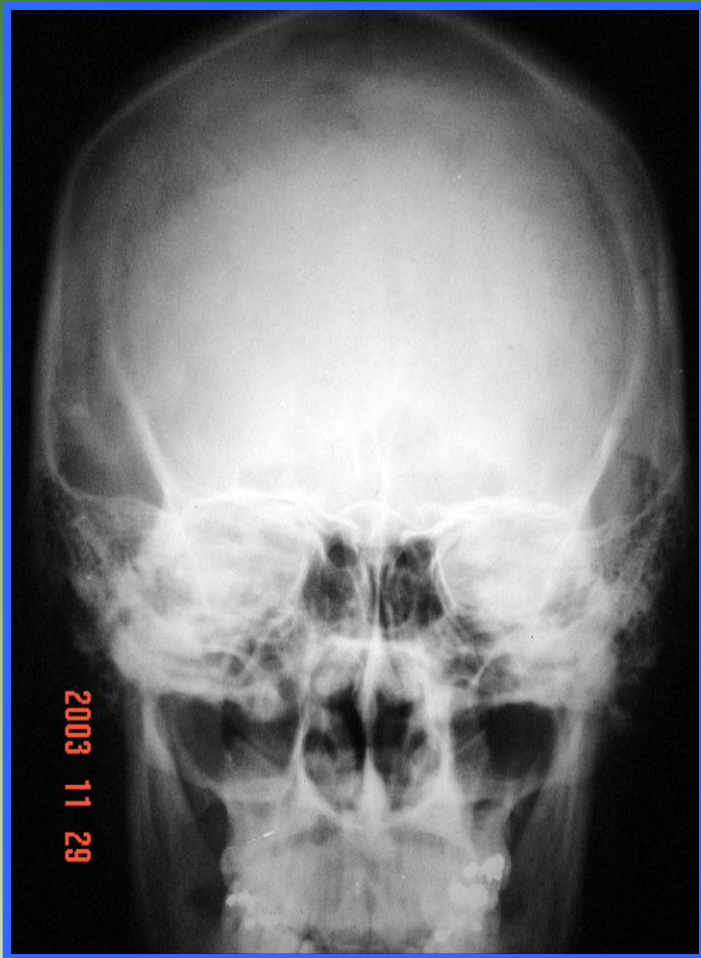
# Objetivos:

- 1. Indicar los estudios imagenológicos al alcance del médico general básico, partiendo de la hipótesis diagnóstica creada, ante pacientes reales o simulados.
- 2. Interpretar el estudio de cráneo simple, tomando en cuenta los datos clínicos del paciente.
- 3. Integrar los resultados de los estudios ofrecidos por el imagenólogo al proceso diagnóstico de los síndromes del sistema nervioso.

# Exámenes Imagenológicos

- Rx Cráneo Simple.
- TAC.
- RMN.
- US Doppler.
- Opacificaciones vasculares.

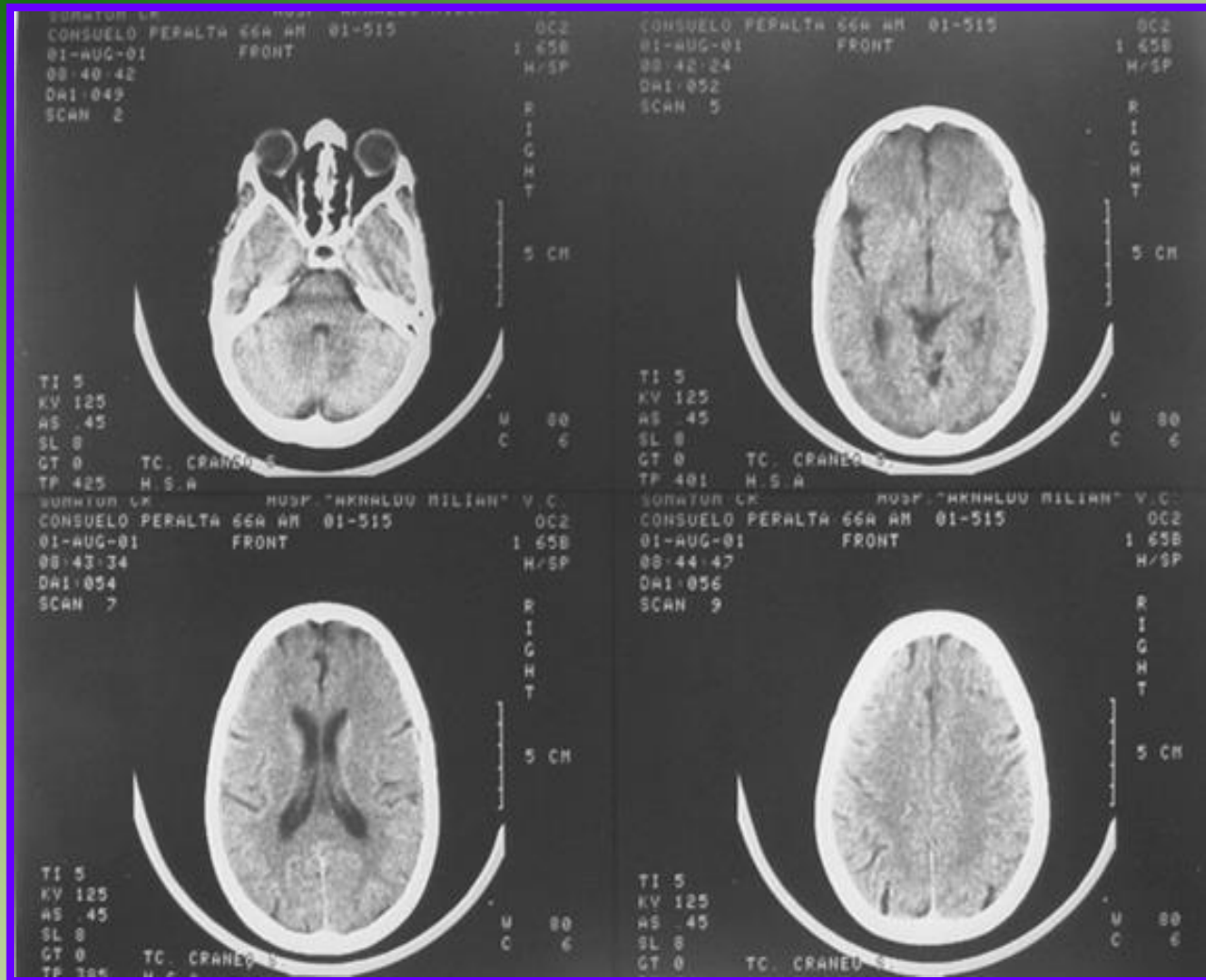
# Cráneo Simple



# TOMOGRAFIA AXIAL COMPUTARIZADA



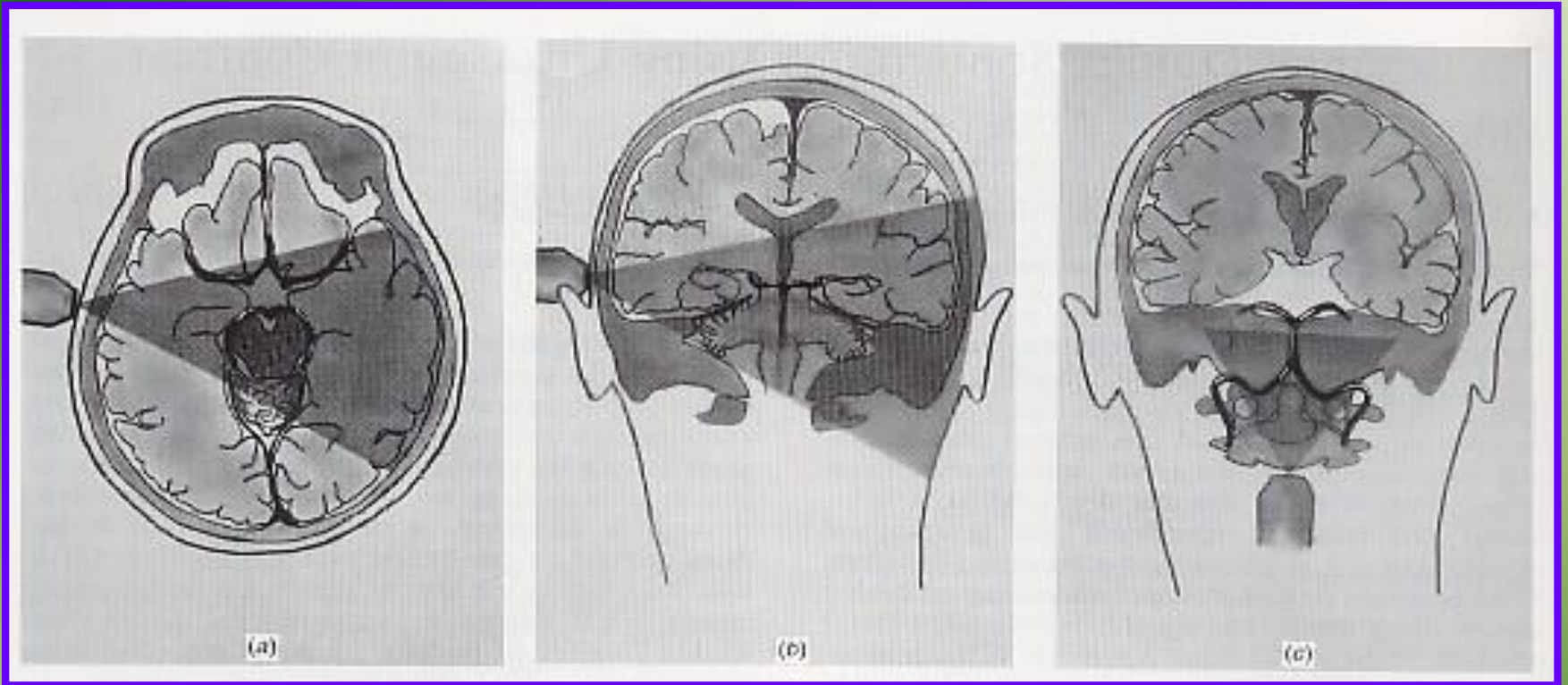
# TAC



# US Doppler



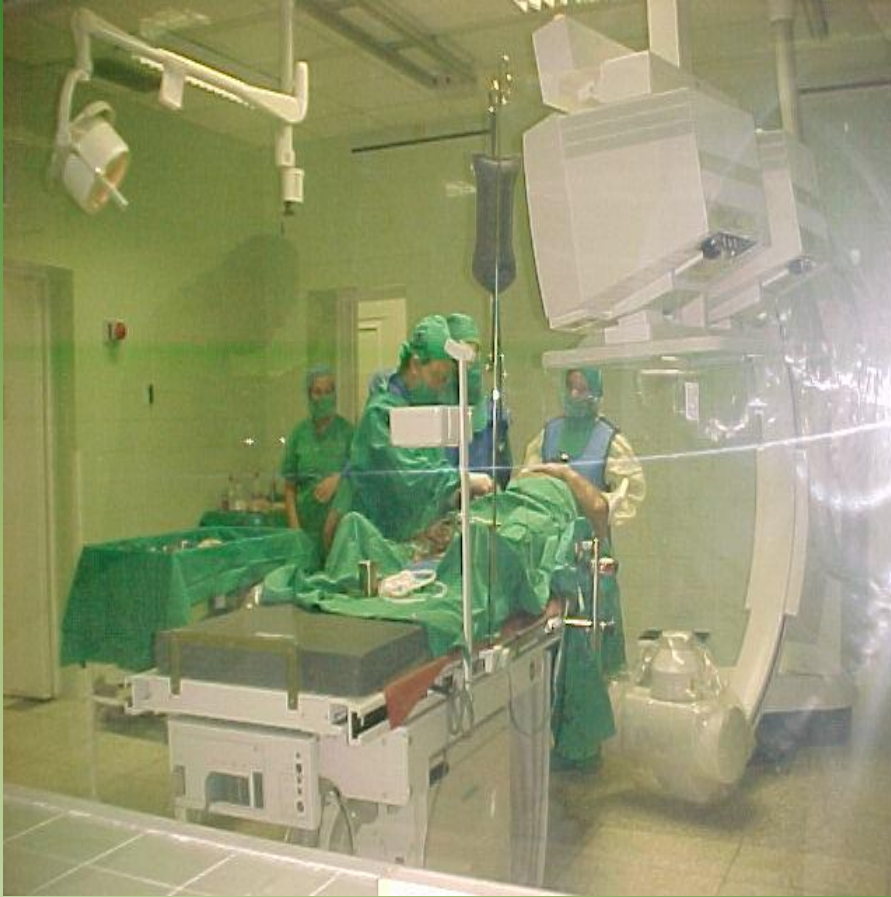


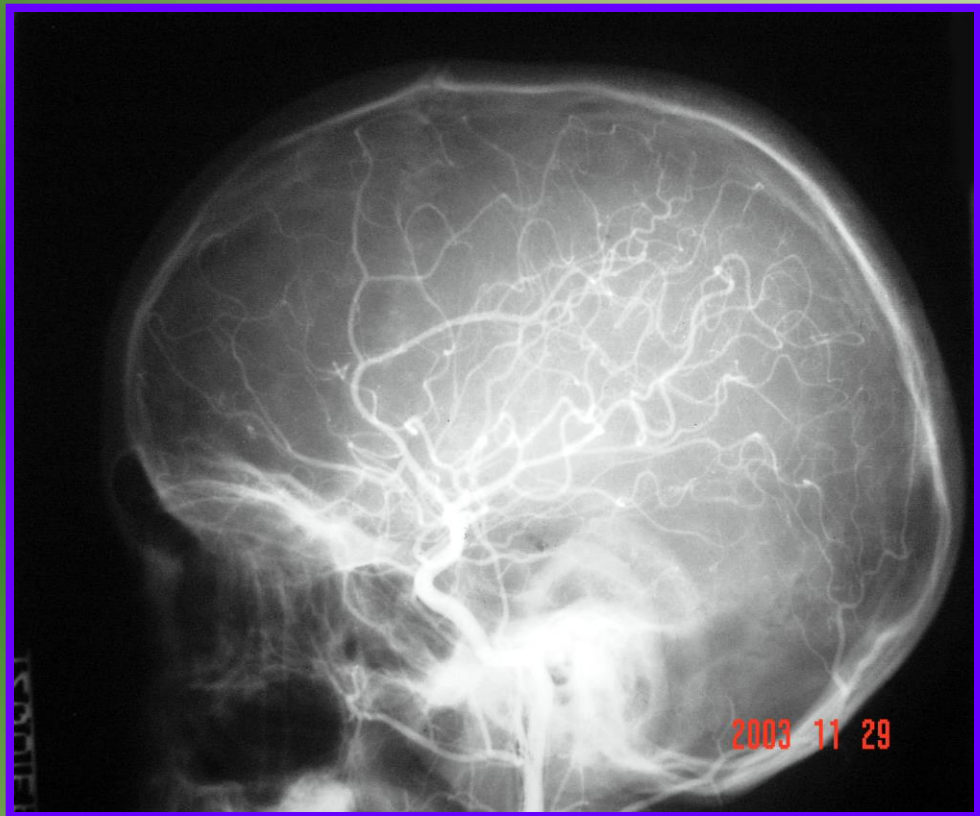
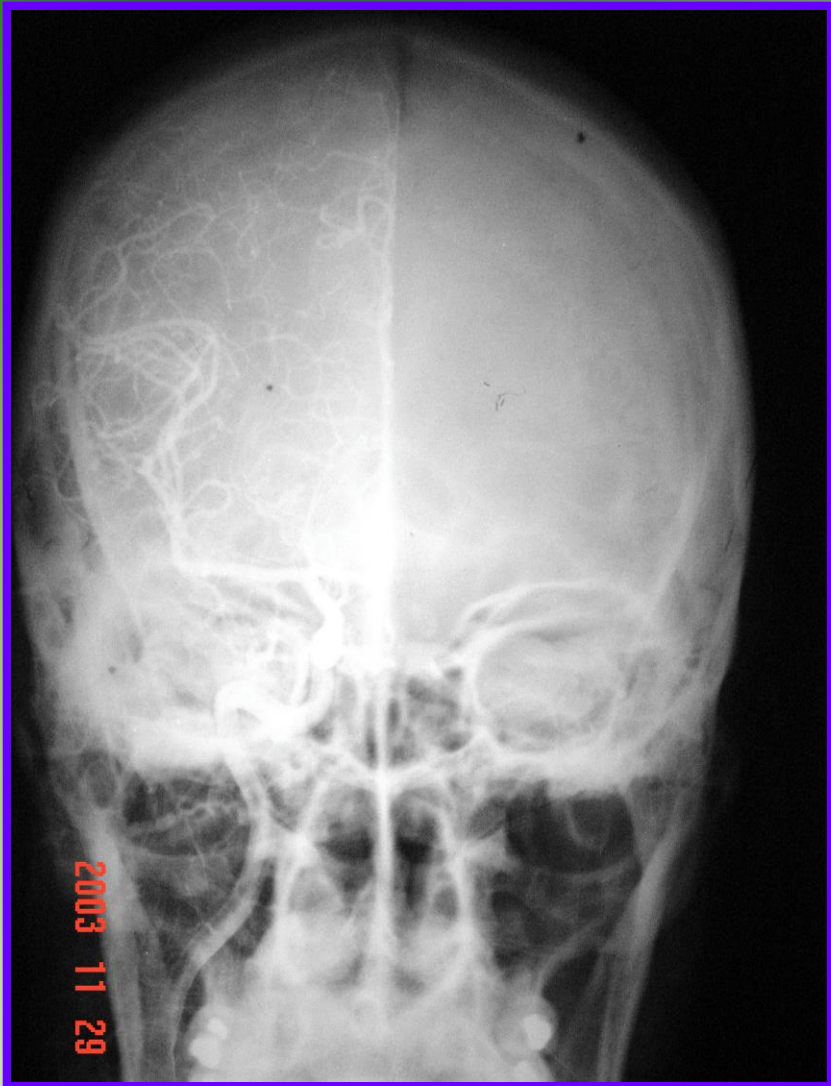**Ecografía Transfontanelar, via escama del hueso temporal y via agujero magno.**

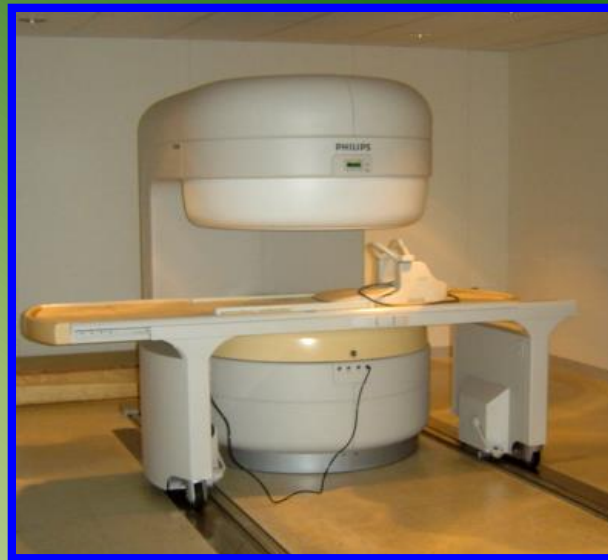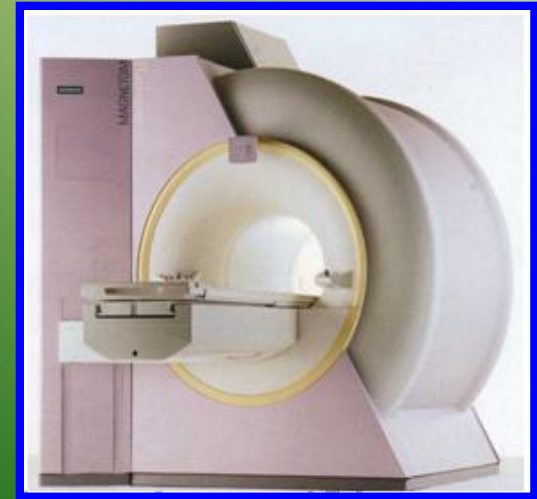



# Opacificaciones Vasculares

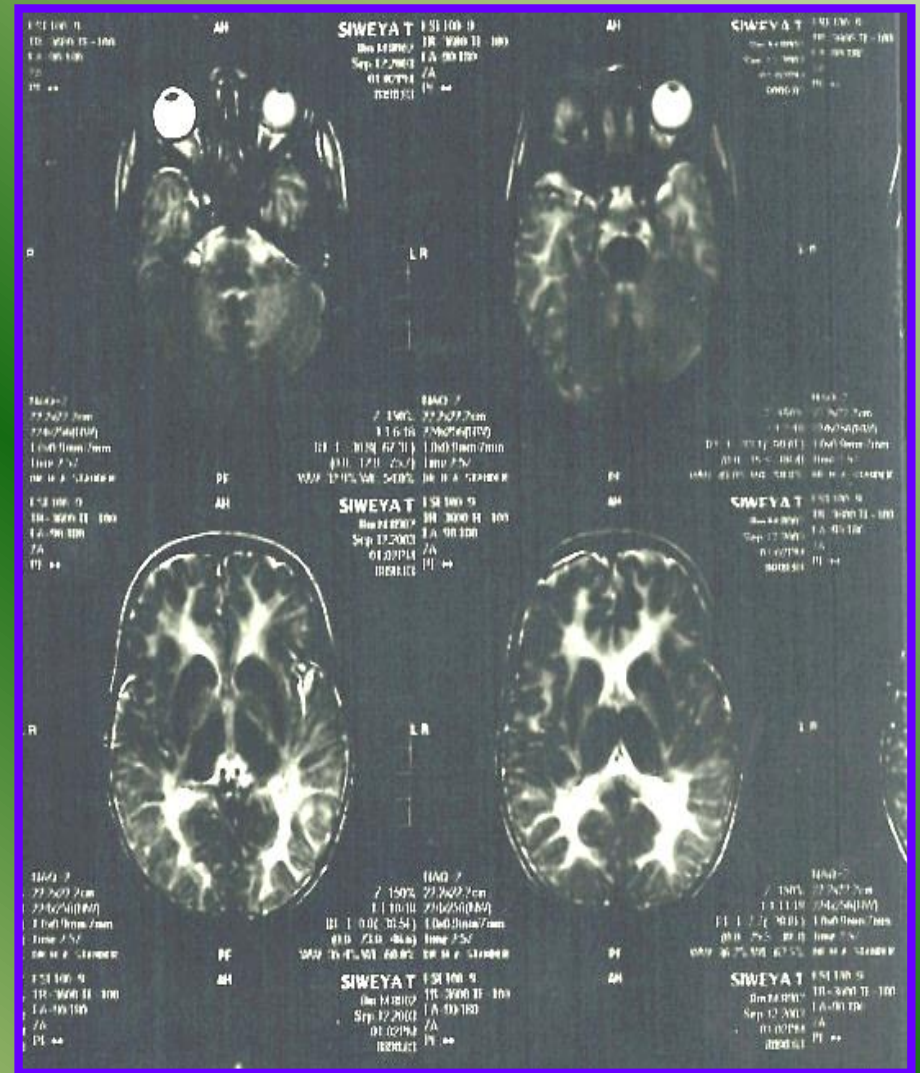
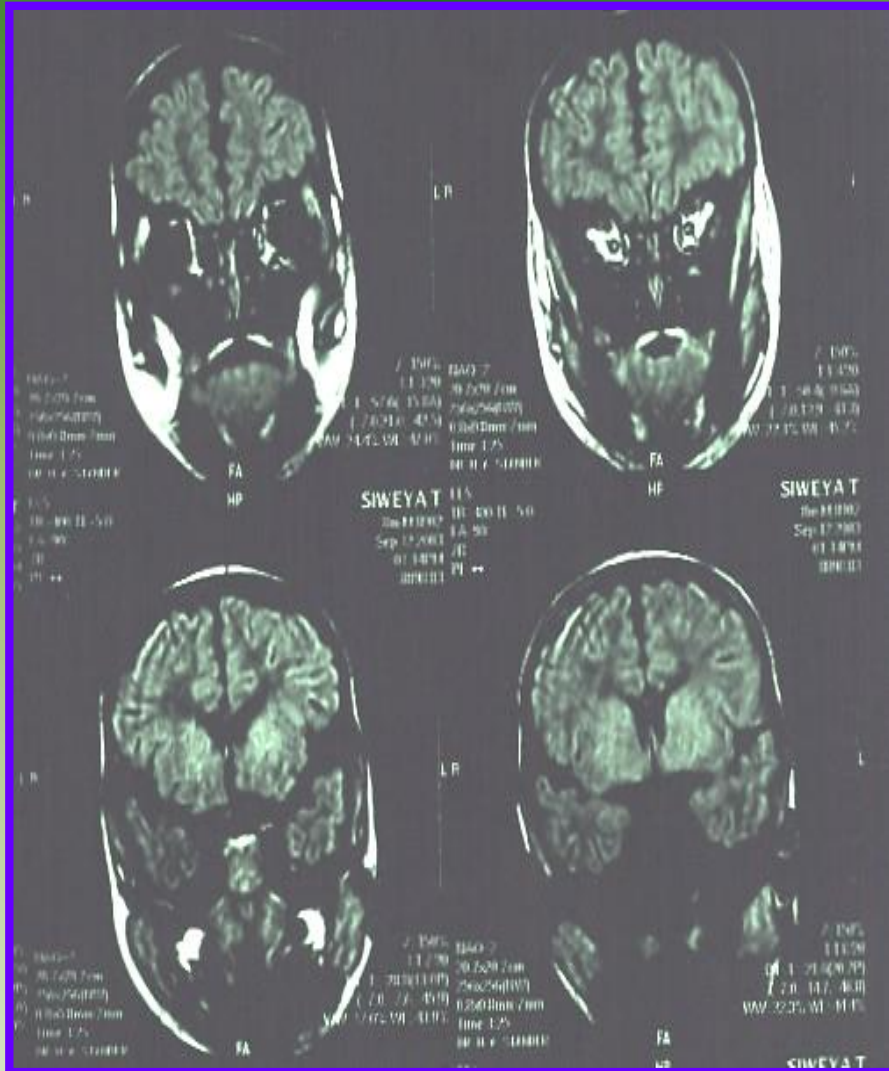




# RESONANCIA MAGNETICA NUCLEAR

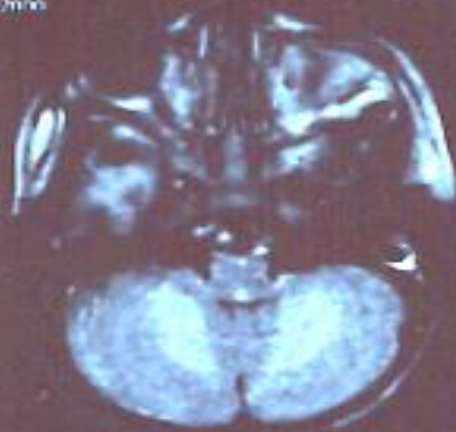

# RESONANCIA MAGNETICA NUCLEAR



FSI 120 11  
TR=10000 TI=120  
FA=90 100 TI=2000  
73  
PT=++

AH

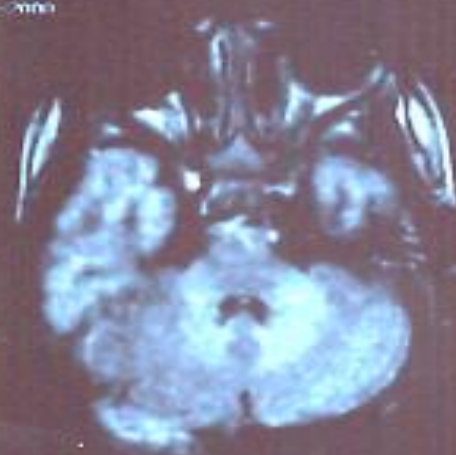

R

SIWEYA T  
08/14/00  
Sep 12 2000  
01:07:54  
189013

FSI 120 11  
TR=10000 TI=120  
FA=90 100 TI=2000  
73  
PT=++

AH



LR

SIWEYA T  
08/14/00  
Sep 12 2000  
01:07:54  
189013

FAO=7  
22.4x22.4cm  
22.4x25.0(FAO)  
1.0x0.9mm/3mm  
Time:0:50  
08/14/00 17:00:00

PF

AH

Z: 150%  
1.1 10.20  
CT: 1. 35.0 [-75.21]  
1. 7.0 10.3 [-81.15]  
WW: 50.0% WL: -46.35

FAO=7  
22.4x22.4cm  
22.4x25.0(FAO)  
1.0x0.9mm/3mm  
Time:0:50  
08/14/00 17:00:00

PF

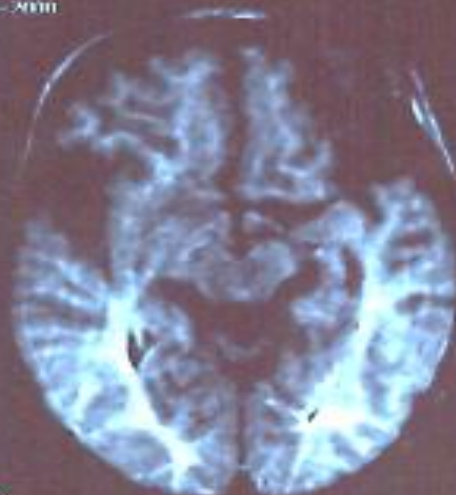
AH

Z: 150%  
1.1 10.20  
CT: 1. 20.0 [-88.30]  
1. 7.0 10.3 [-81.15]  
WW: 50.0% WL: -46.35

FSI 120 11  
TR=10000 TI=120  
FA=90 100 TI=2000  
73  
PT=++

PF

AH



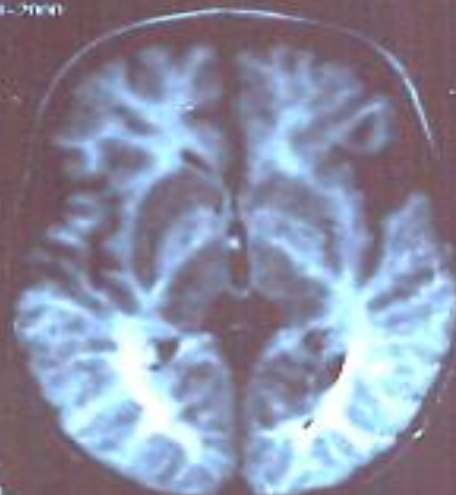
R

SIWEYA T  
08/14/00  
Sep 12 2000  
01:07:54  
189013

FSI 120 11  
TR=10000 TI=120  
FA=90 100 TI=2000  
73  
PT=++

PF

AH



LR

SIWEYA T  
08/14/00  
Sep 12 2000  
01:07:54  
189013

FAO=7  
22.4x22.4cm  
22.4x25.0(FAO)  
1.0x0.9mm/3mm  
Time:0:50  
08/14/00 17:00:00

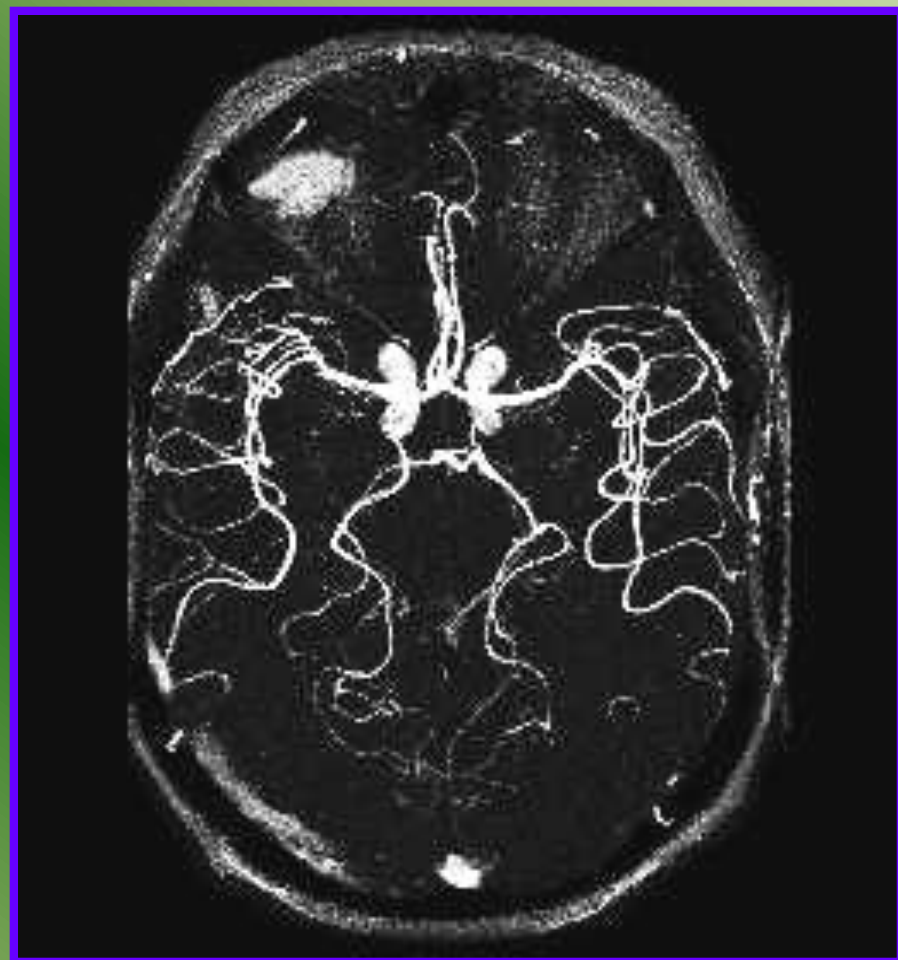
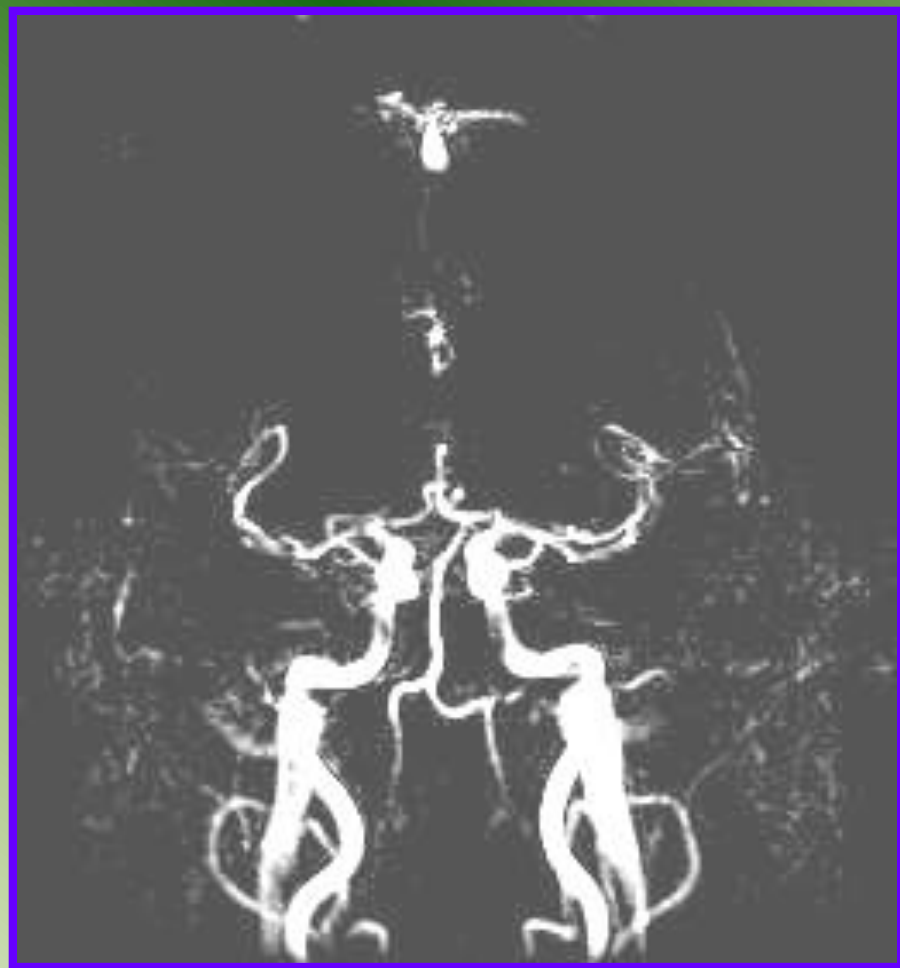PF

Z: 150%  
1.1 10.20  
CT: 1. 2.0 [-42.21]  
1. 7.0 25.5 [-56.1]  
WW: 50.0% WL: -50.45

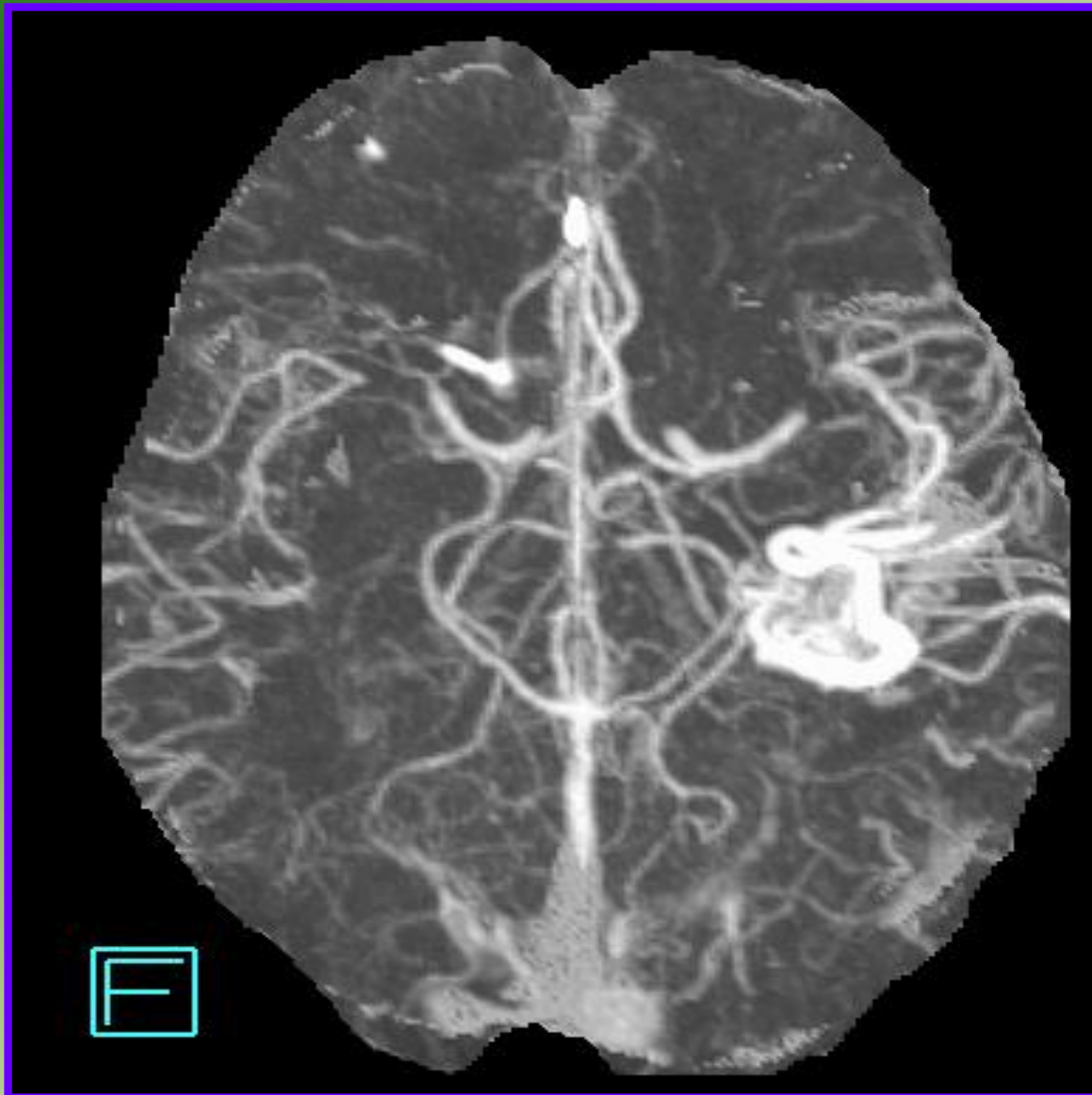
FAO=7  
22.4x22.4cm  
22.4x25.0(FAO)  
1.0x0.9mm/3mm  
Time:0:50  
08/14/00 17:00:00

PF

Z: 150%  
1.1 10.20  
CT: 1. 0.0 [-40.20]  
1. 7.0 27.4 [-41.1]  
WW: 64.0% WL: -10.55

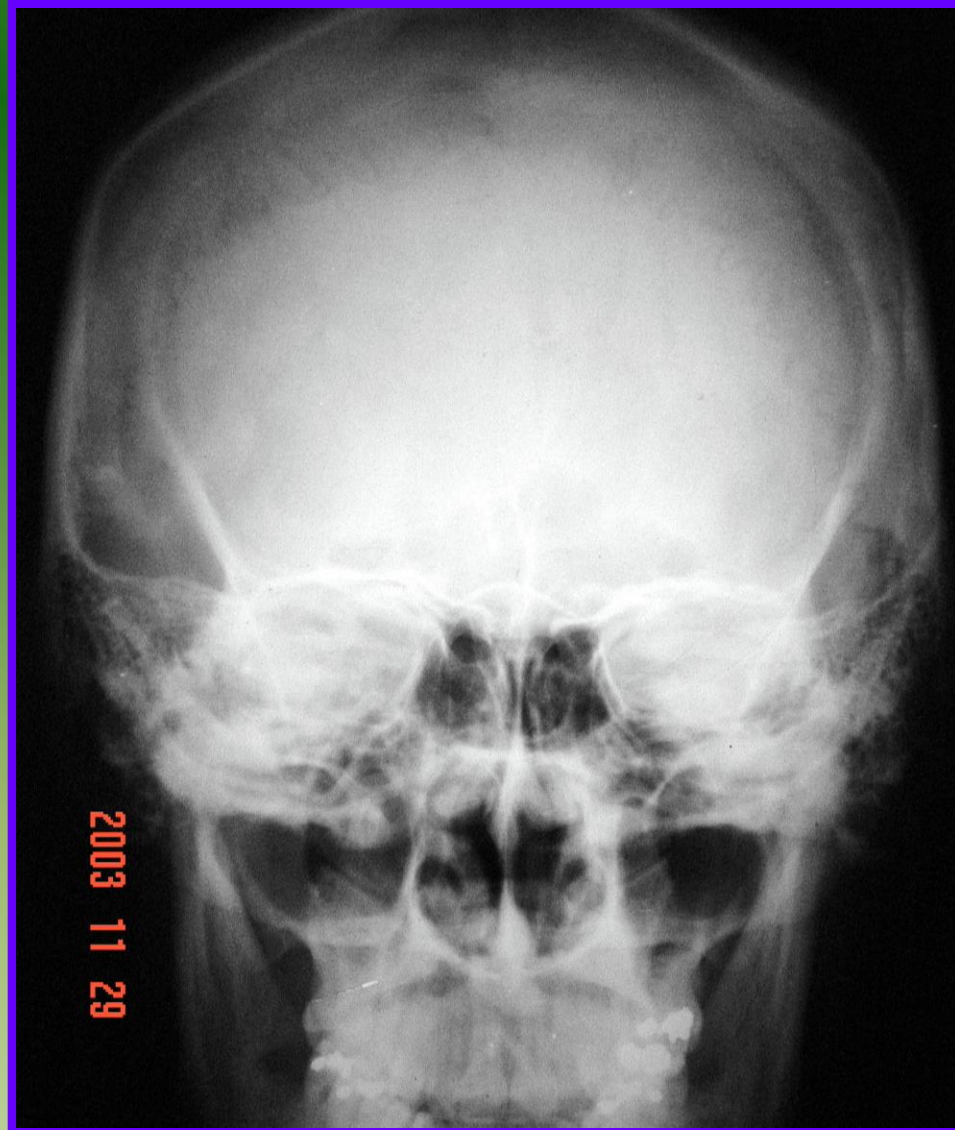



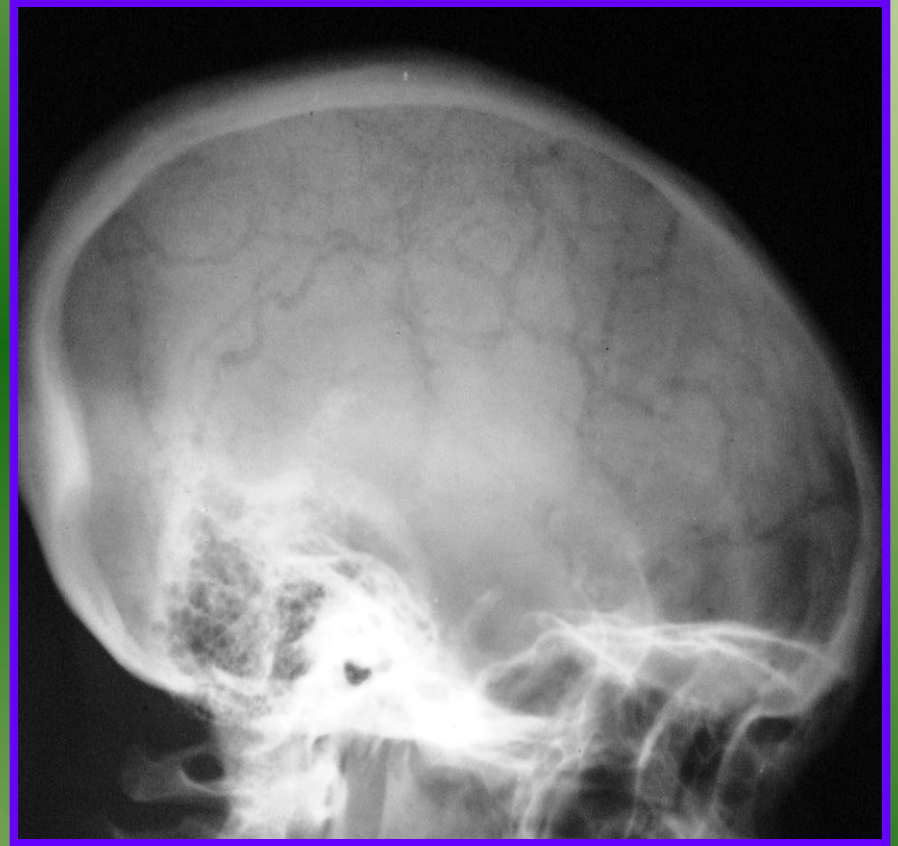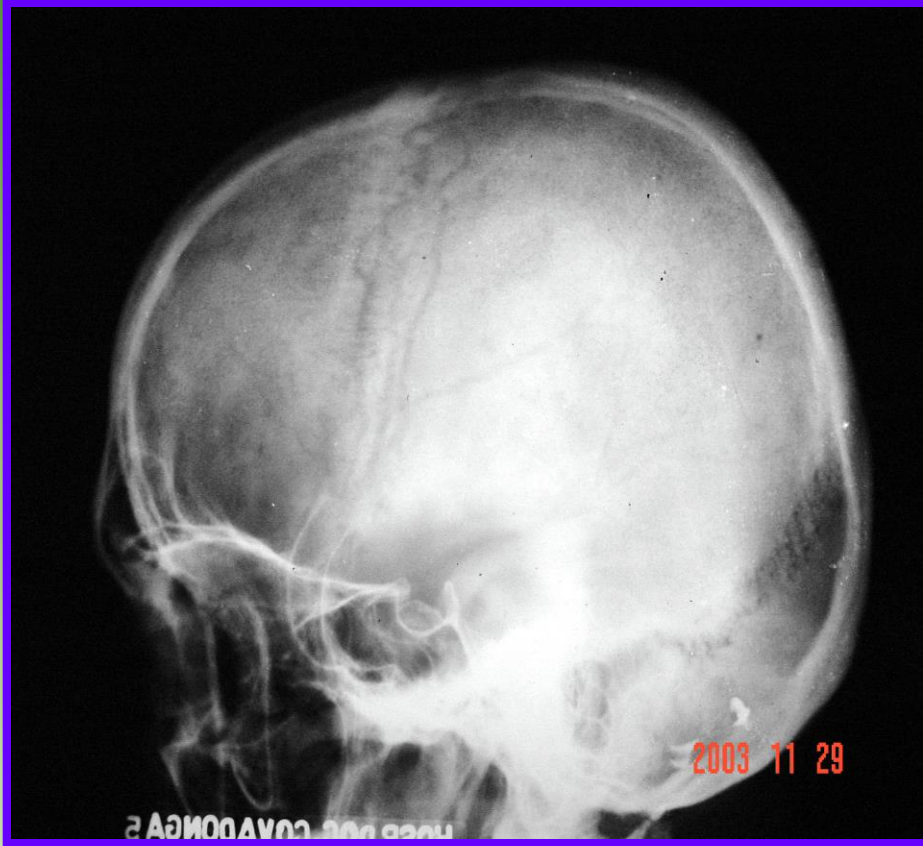


# Cráneo Simple

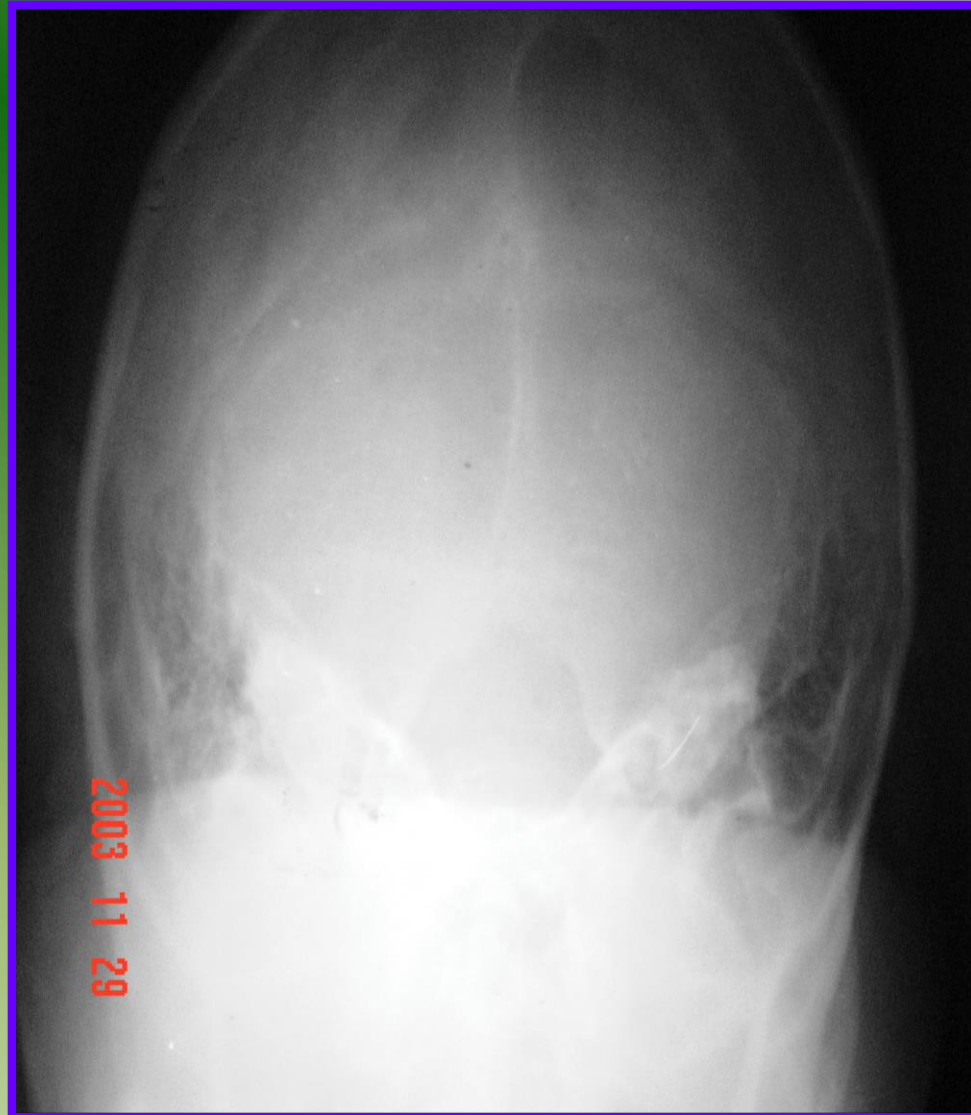# Cráneo Simple AP



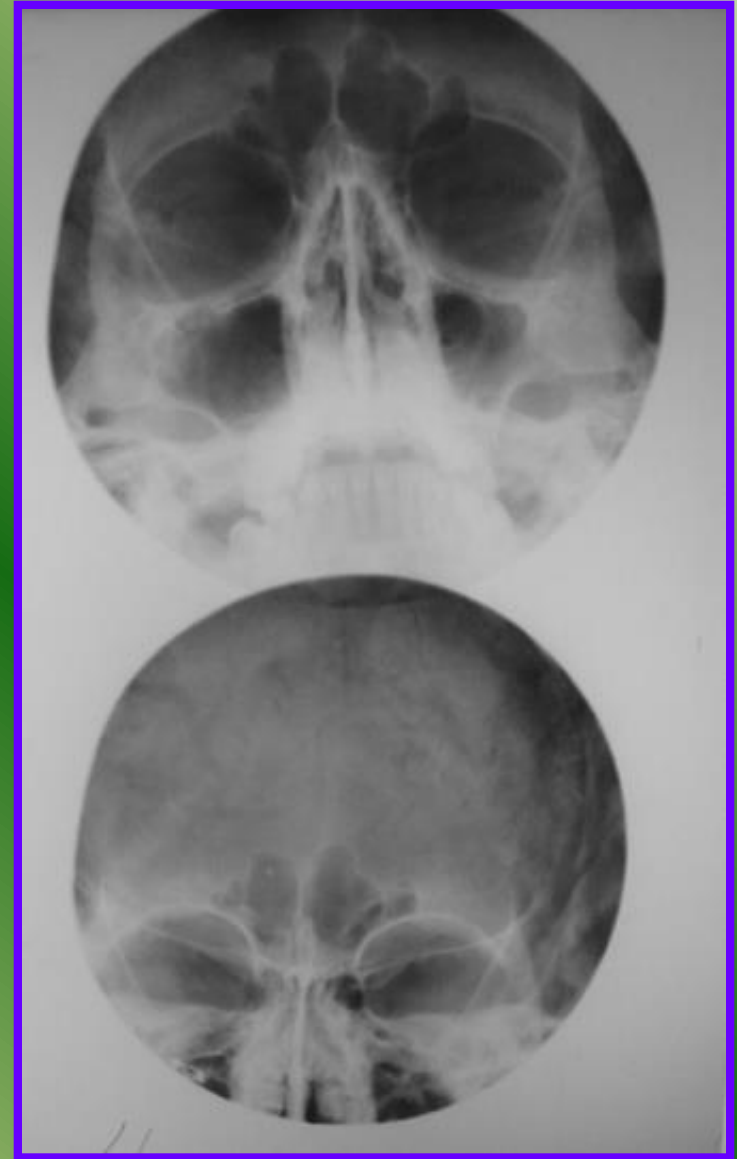
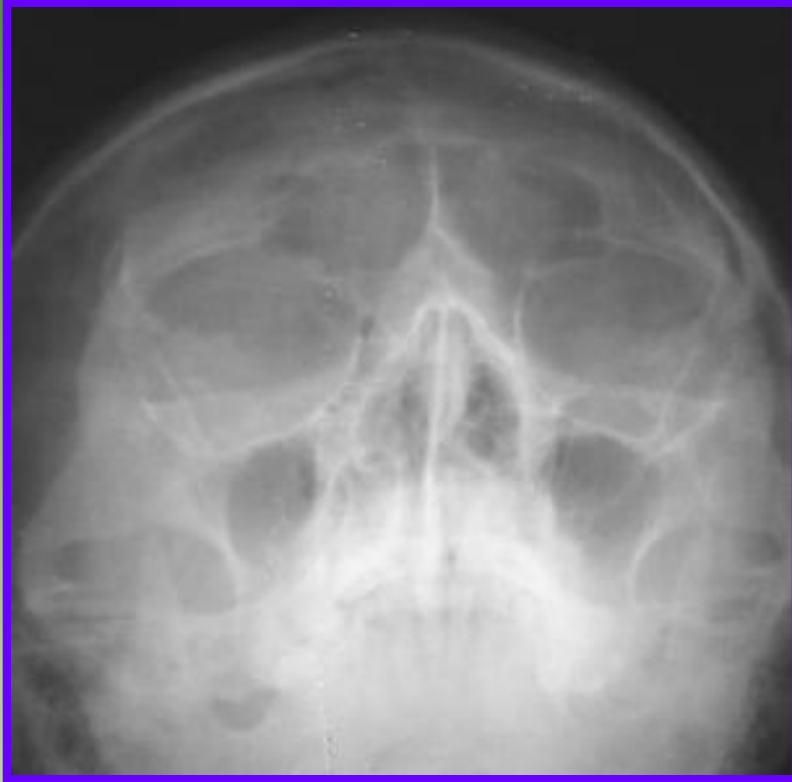
# Cráneo Simple Lateral



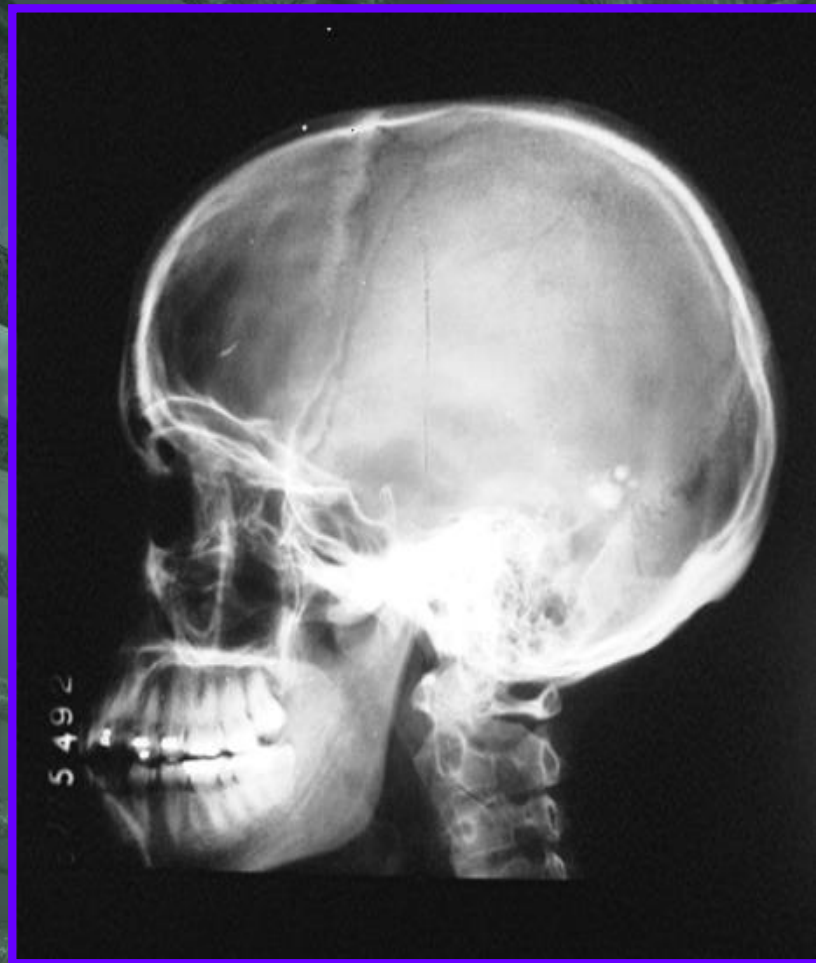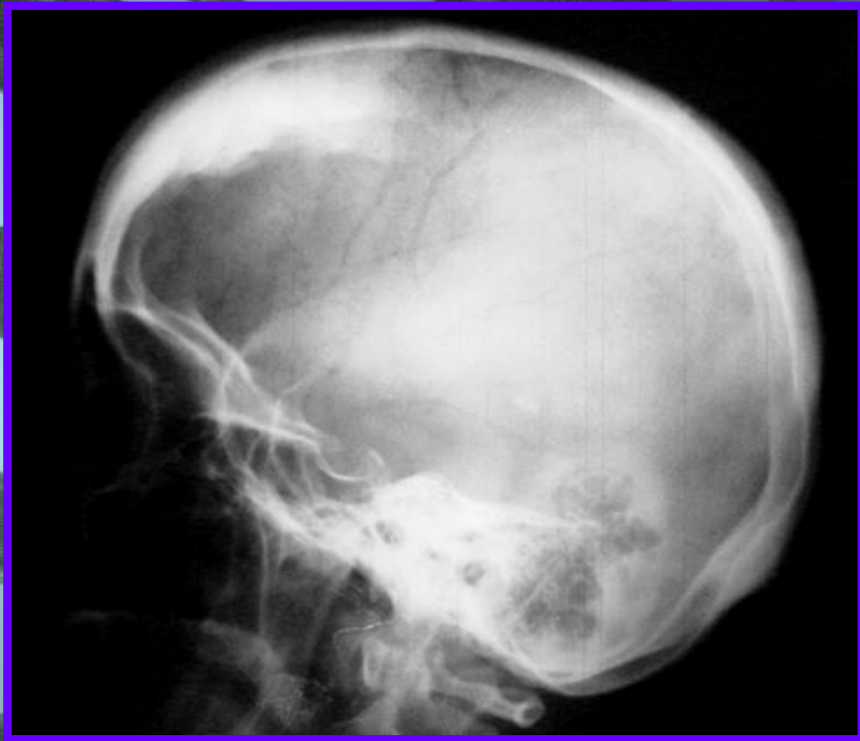# Cráneo Simple vista de Towne



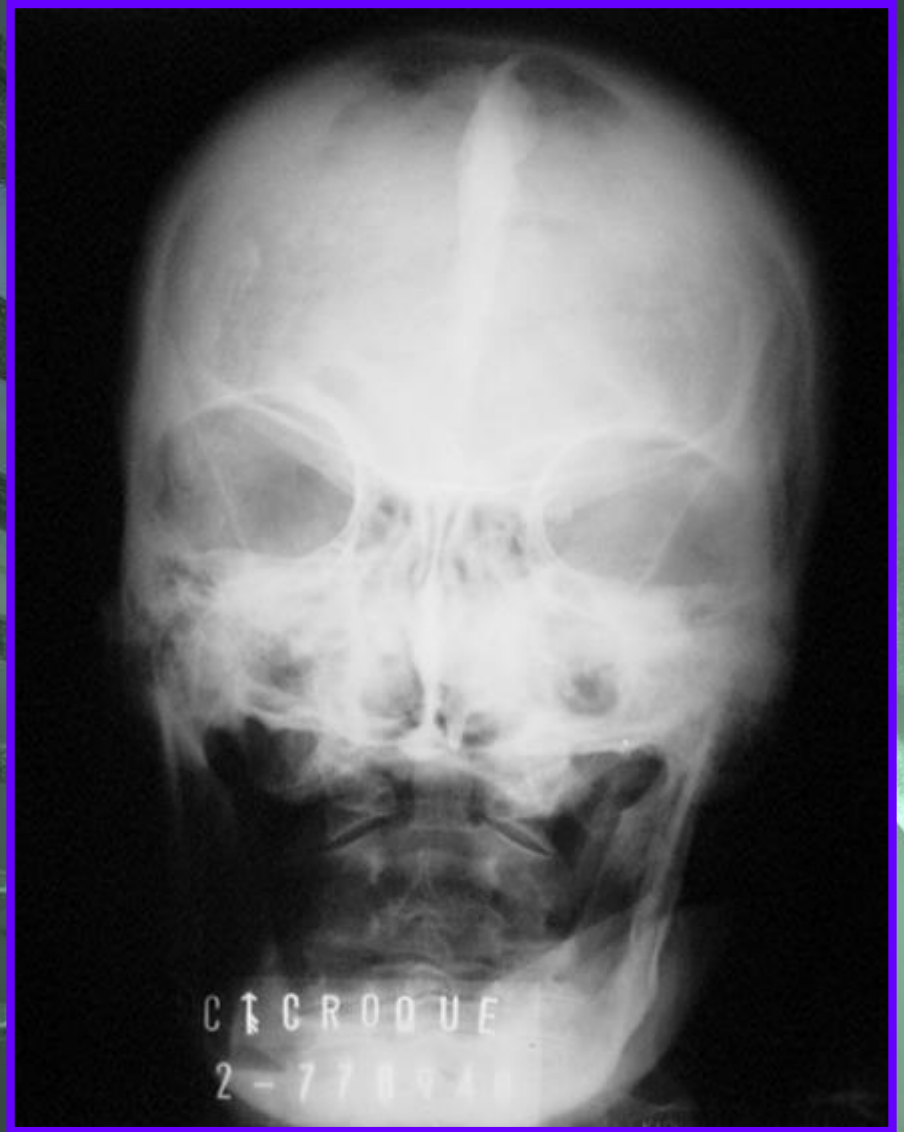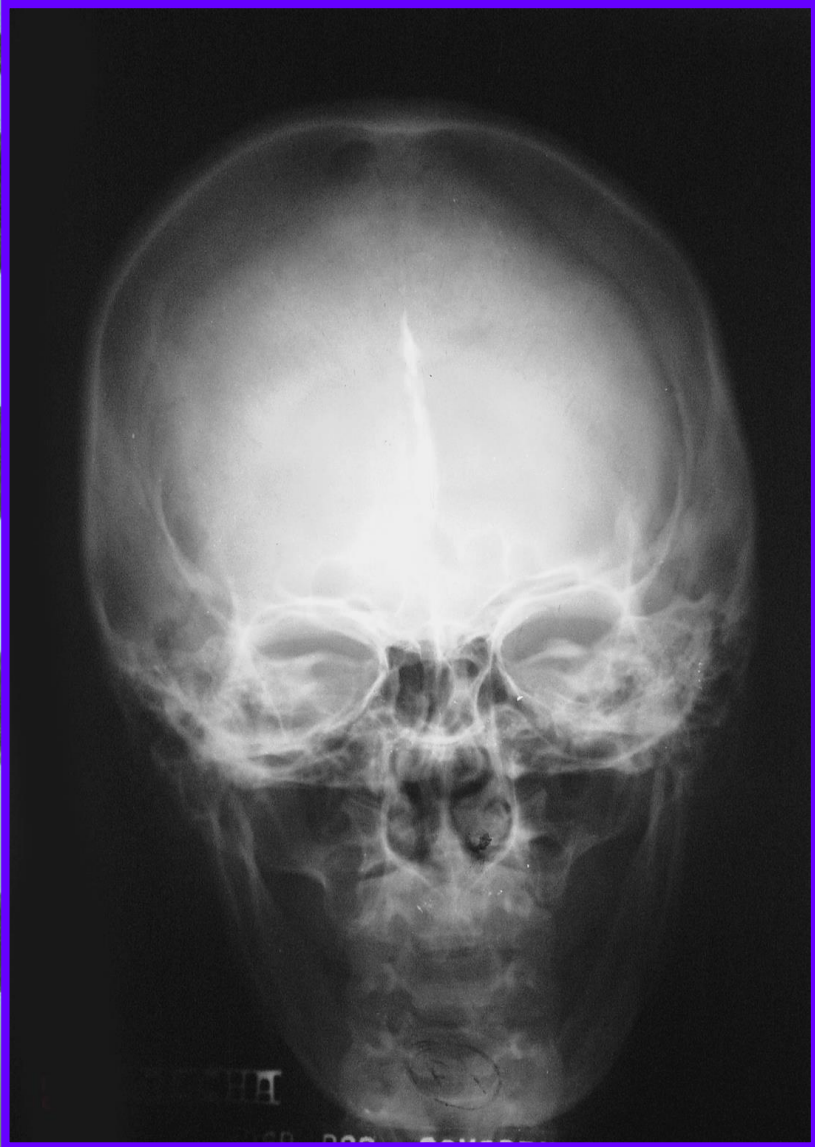# Senos Perinasales



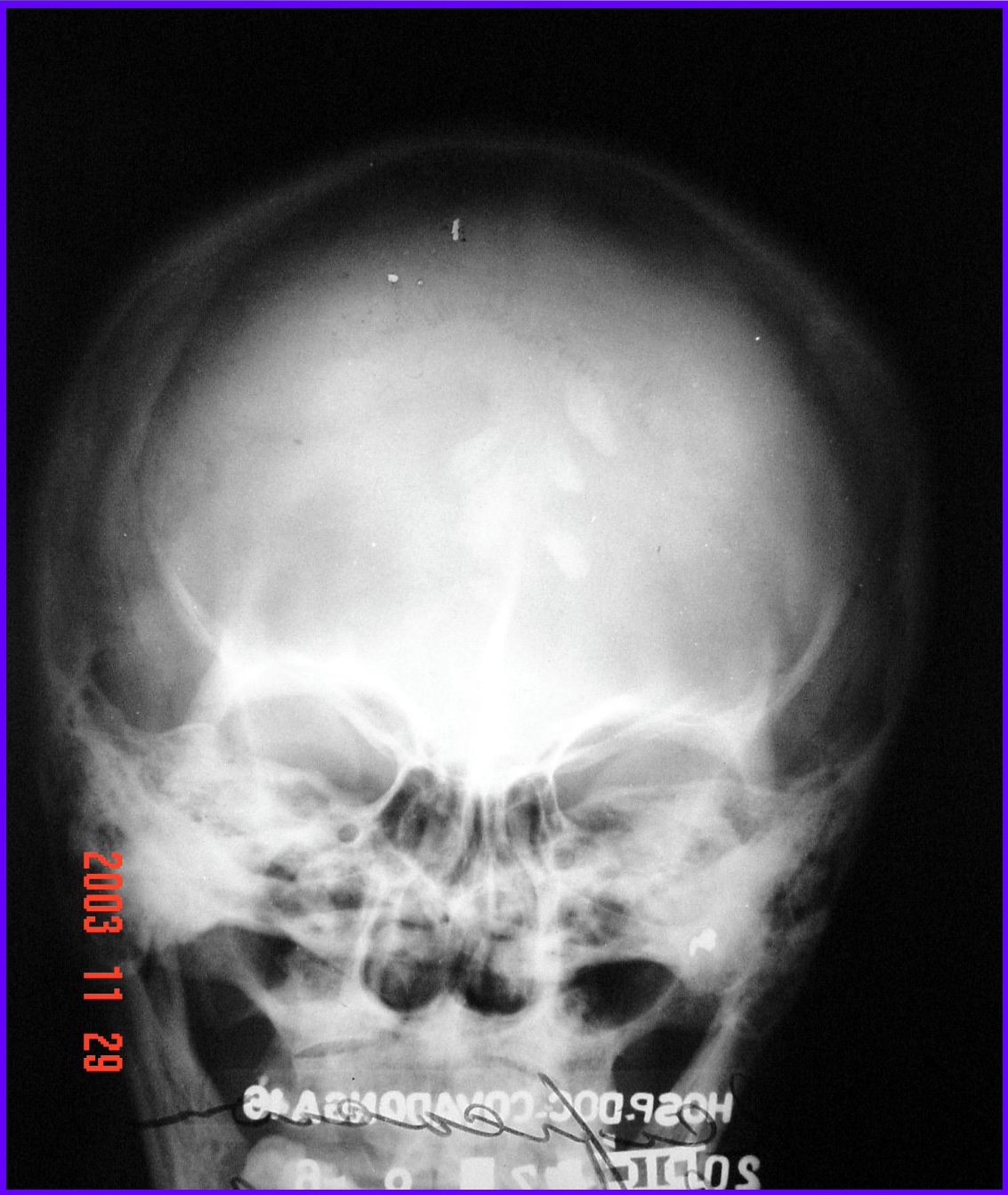# Calcificaciones Normales en el Cráneo Simple





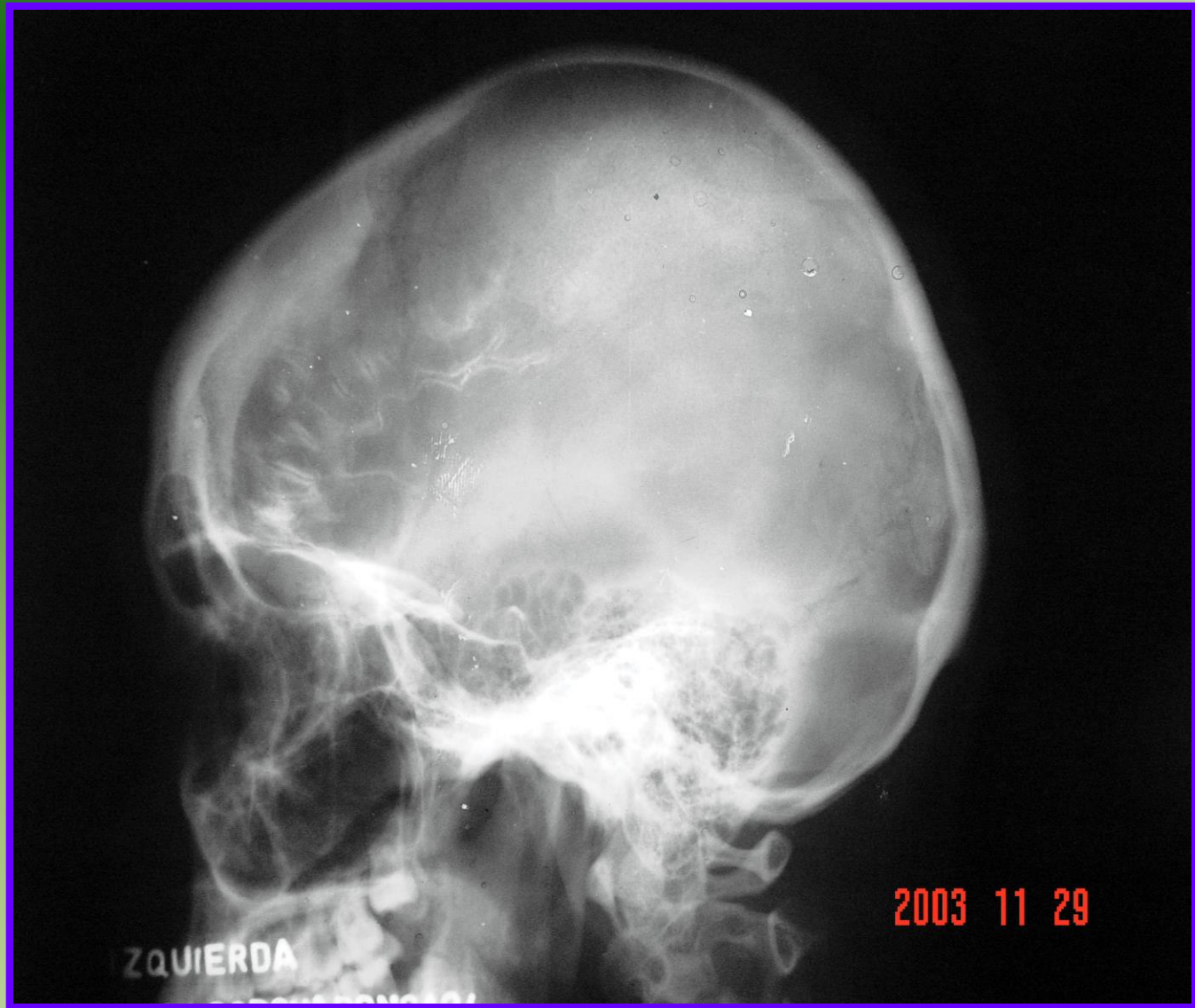

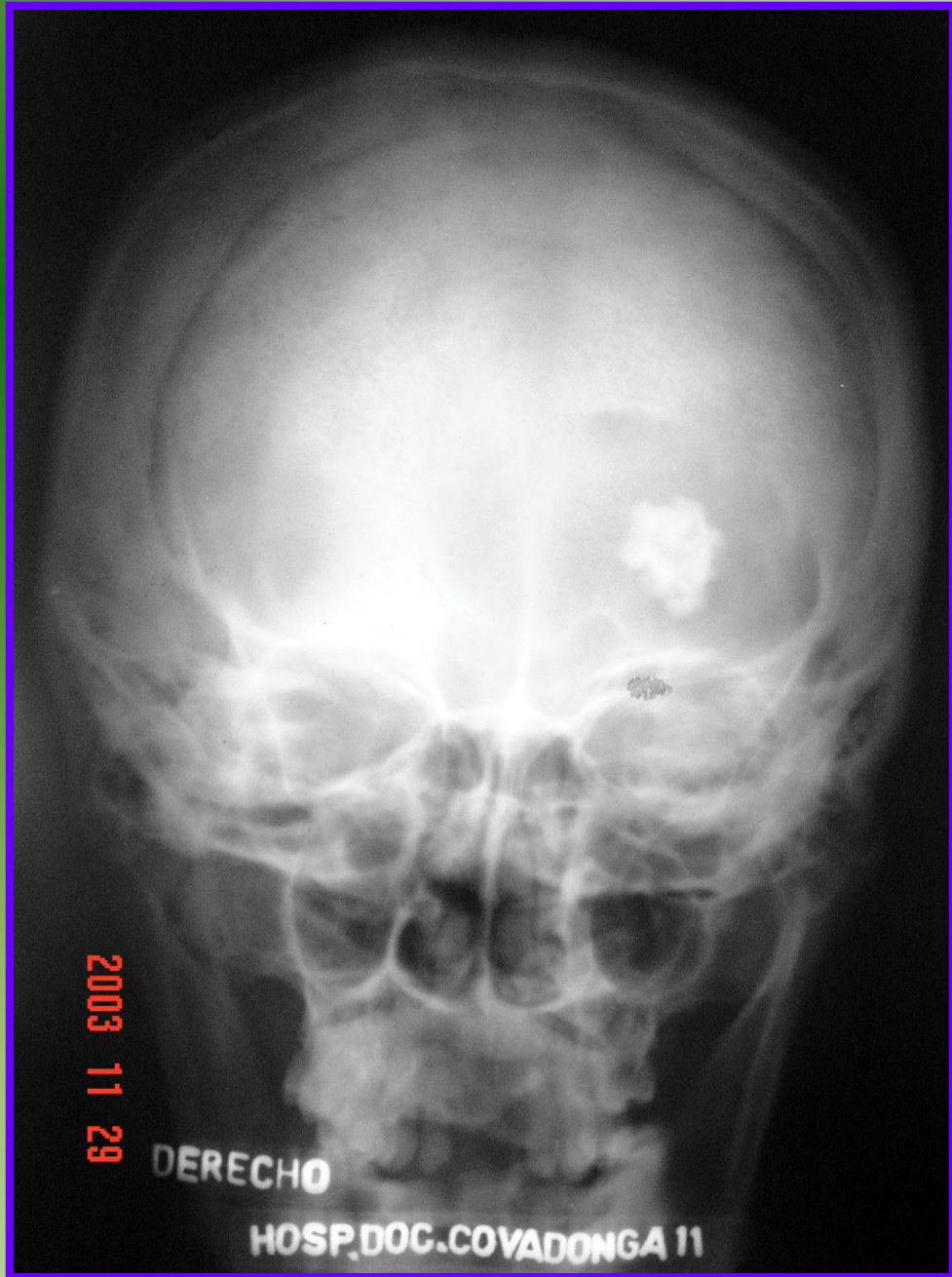# Calcificaciones Patológicas en el Cráneo Simple



2003 11 29

SOE...  
HOSP... COND...  
Dr. O...

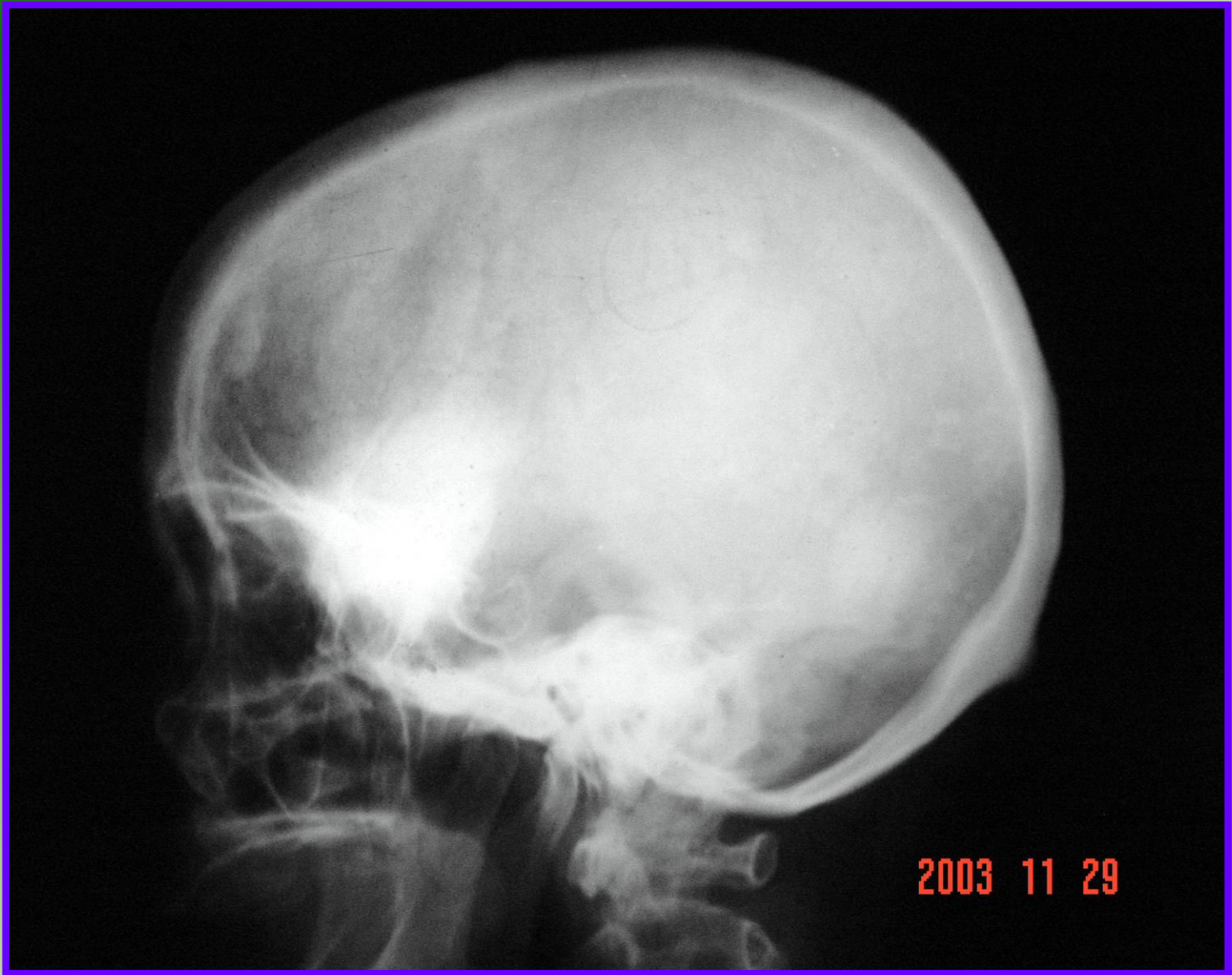




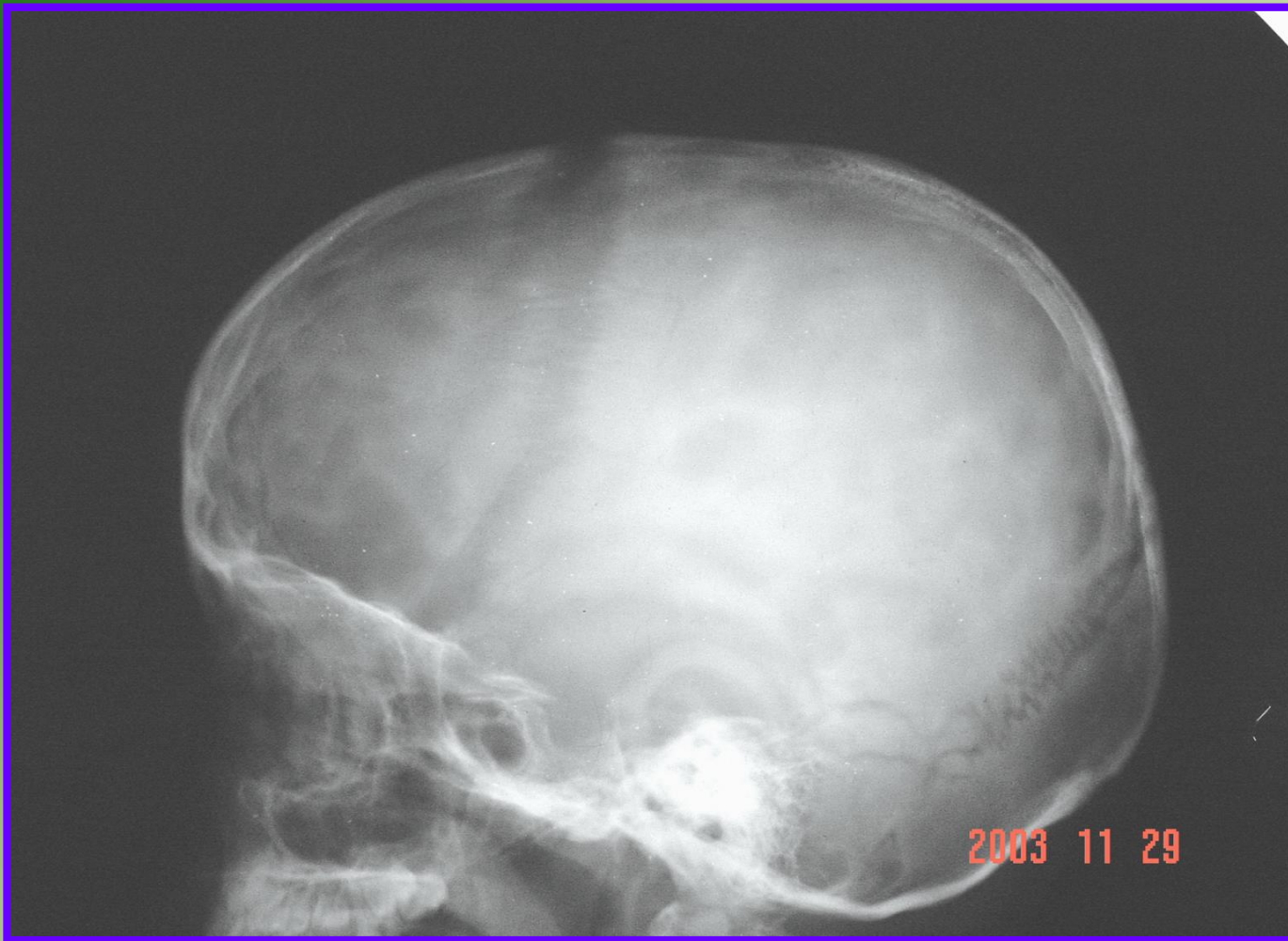
2003 11 29

DERECHO

HOSP.DOC.COVAONGA 11



# Signos de Hipertensión Endocraneana



**Aumento de las impresiones digitiformes  
y  
diastasis de las suturas**

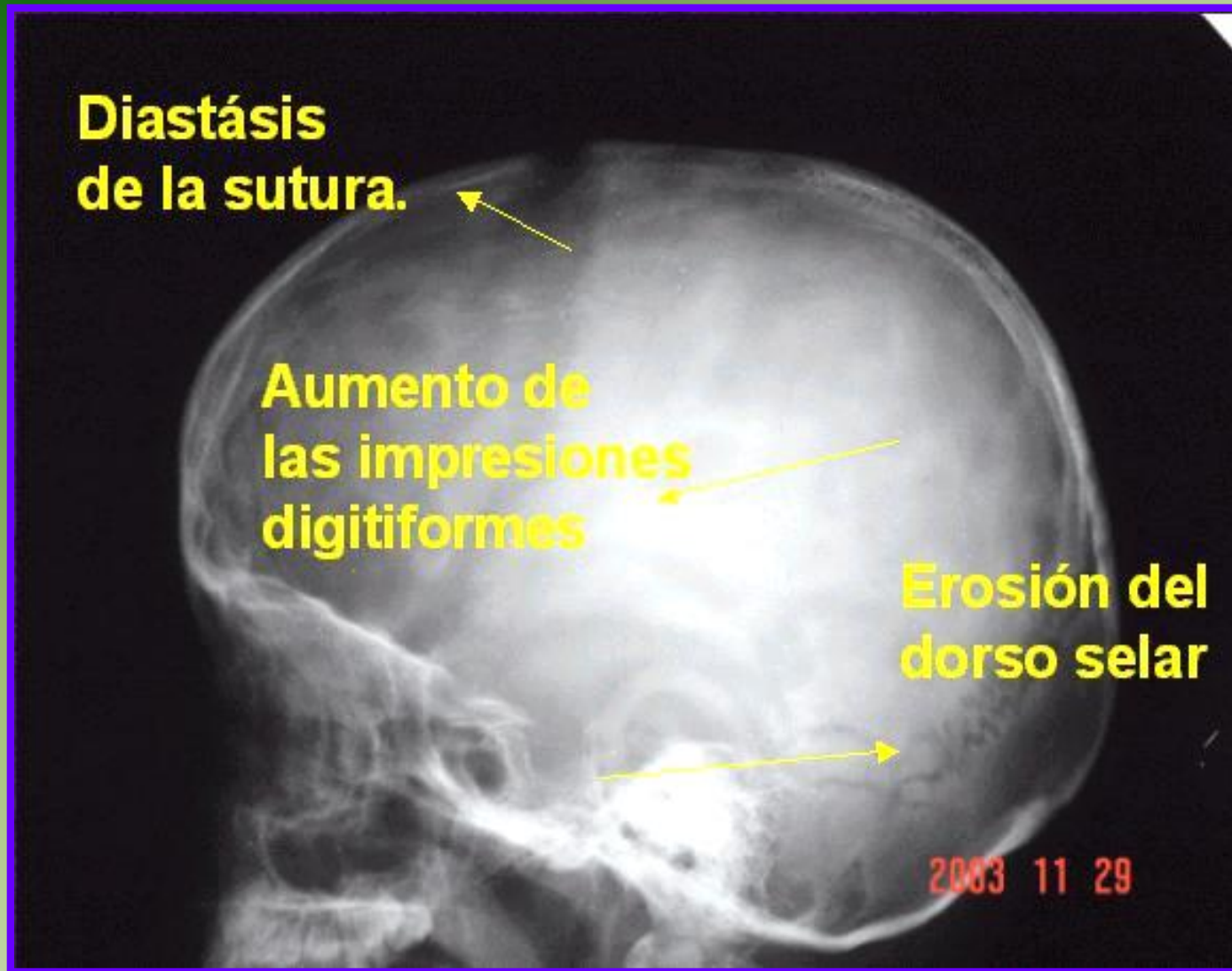

**Diastásis  
de la sutura.**

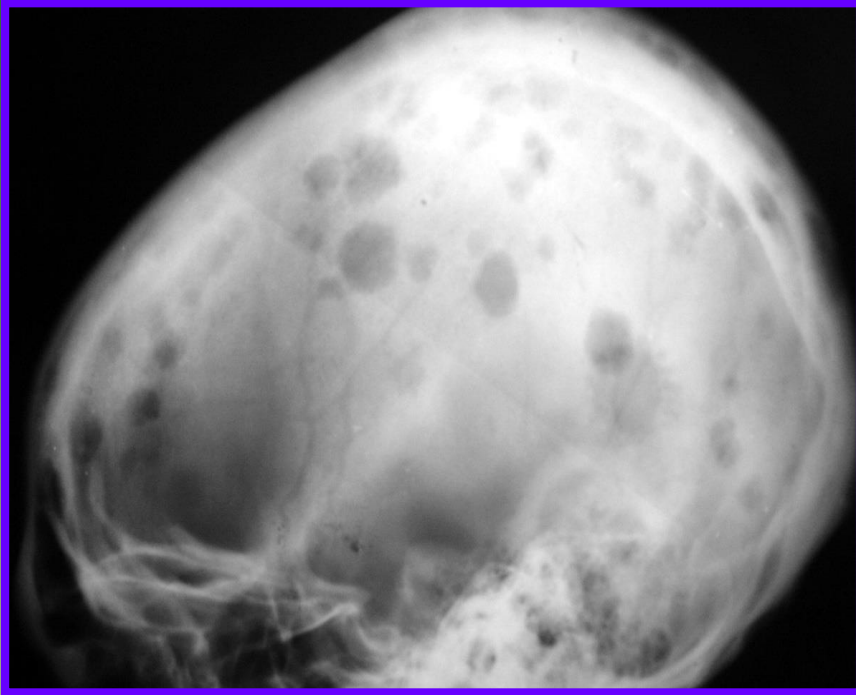
**Aumento de  
las impresiones  
digitiformes**

**Erosión del  
dorso selar**

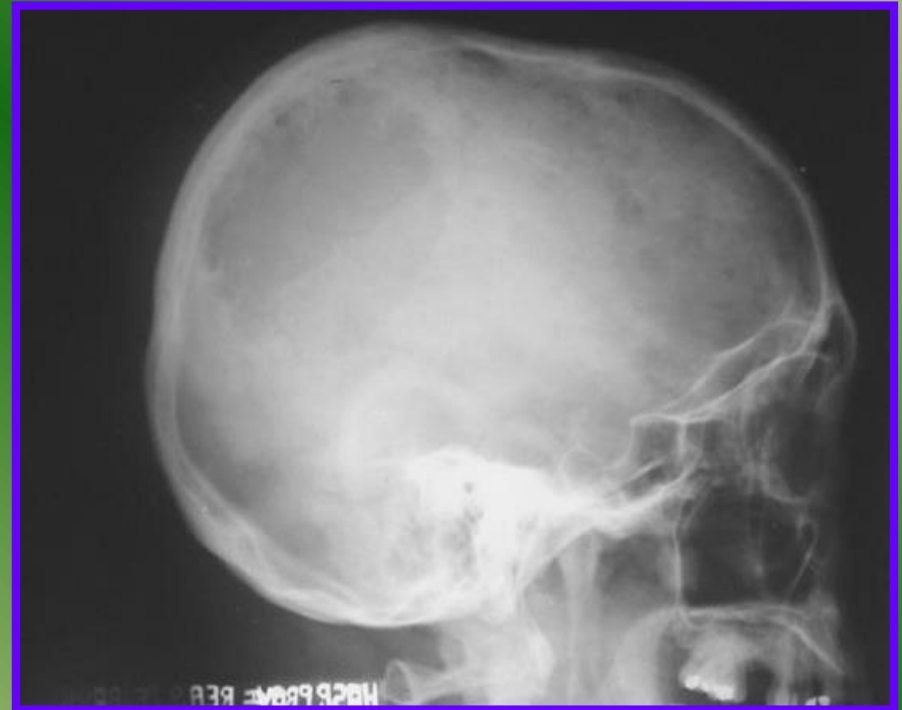2003 11 29



# Lesiones Líticas en el Cráneo Simple



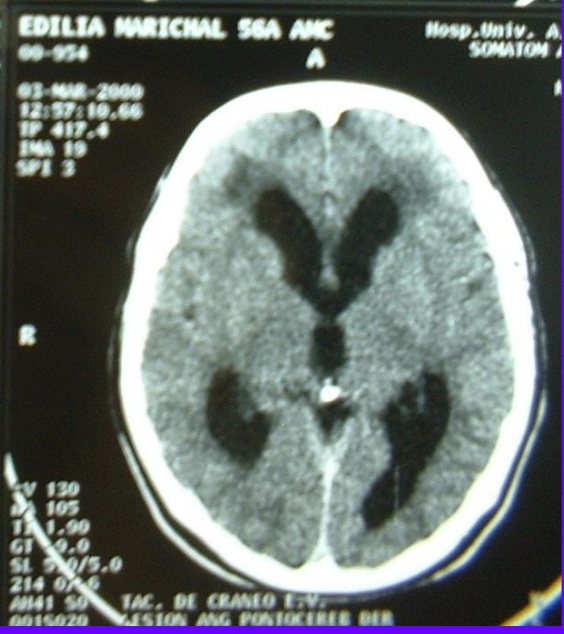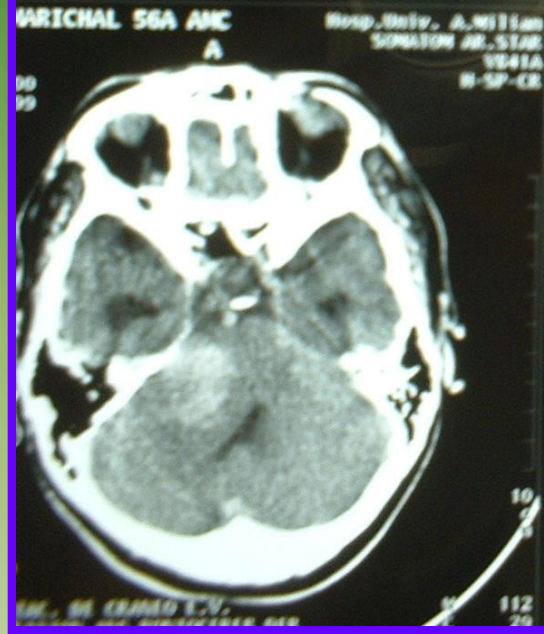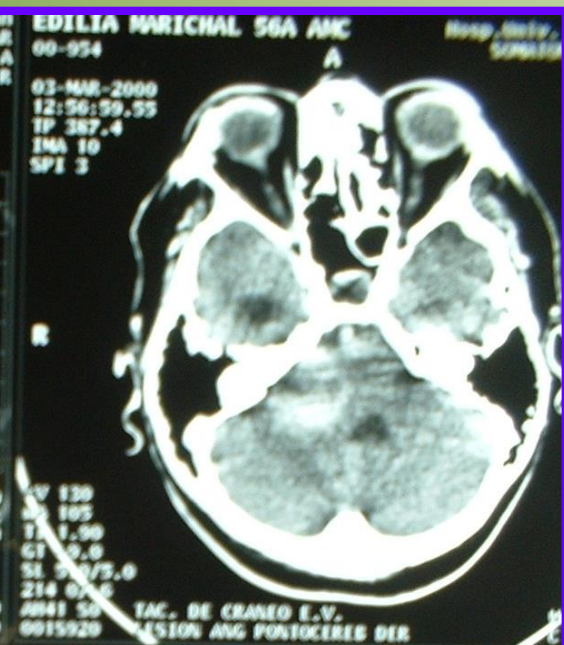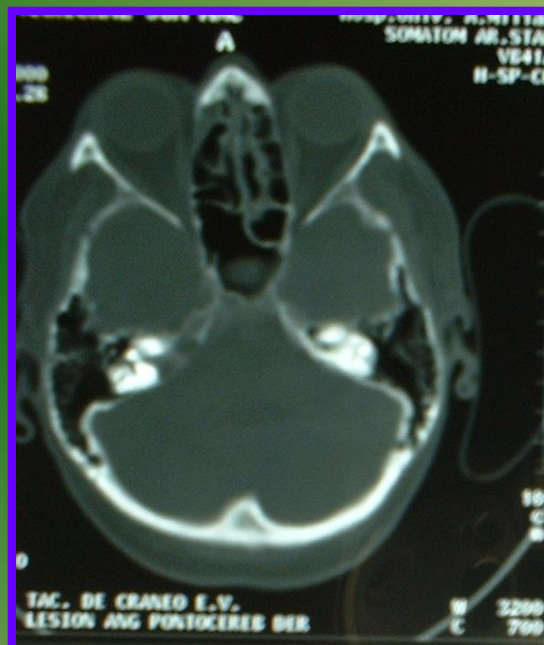
# Osteolysis

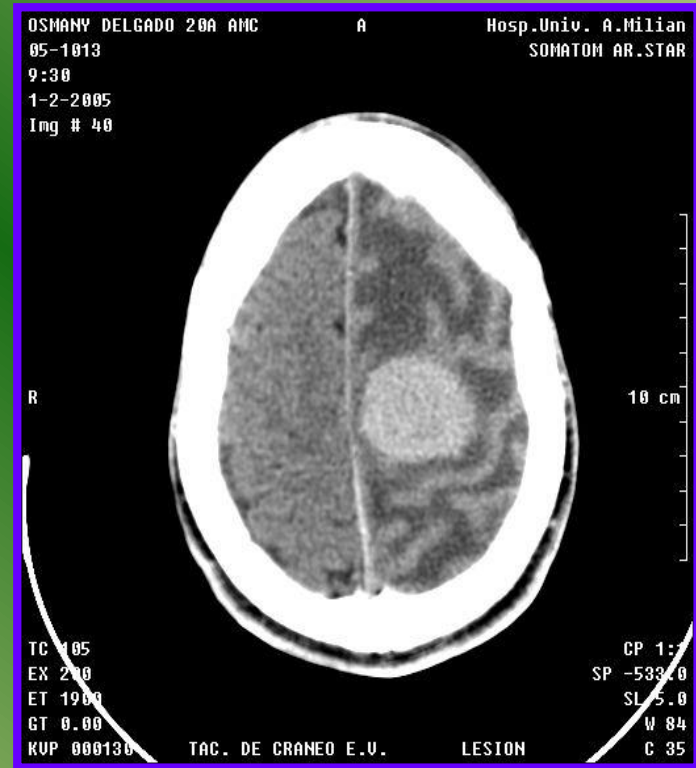
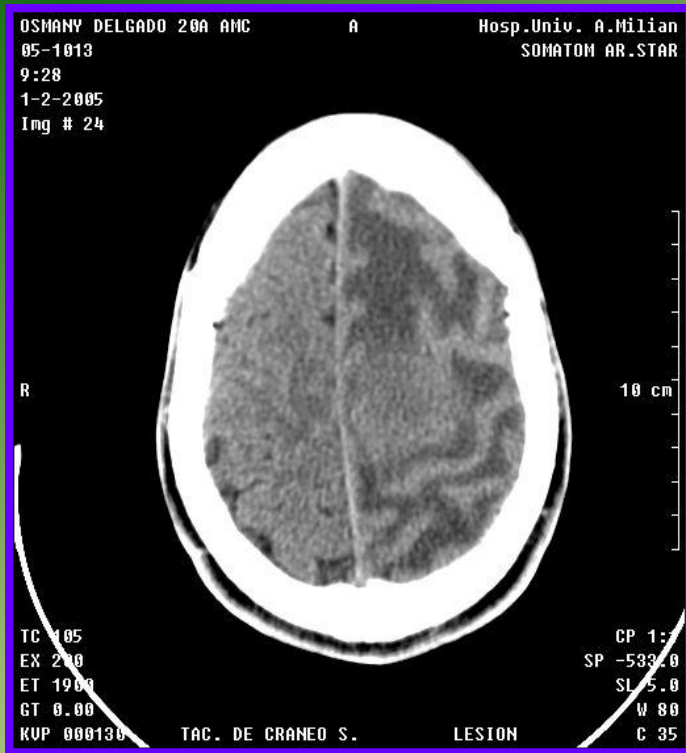

# TOMOGRAFIA AXIAL COMPUTARIZADA

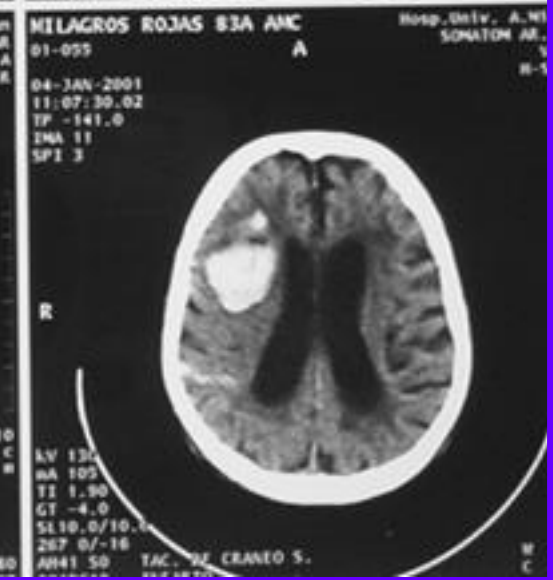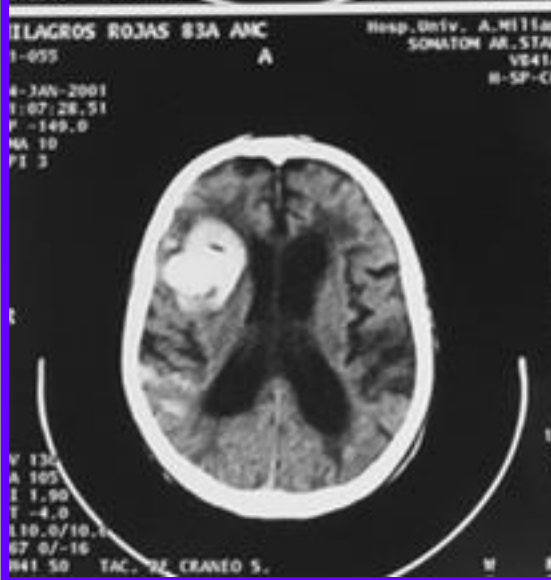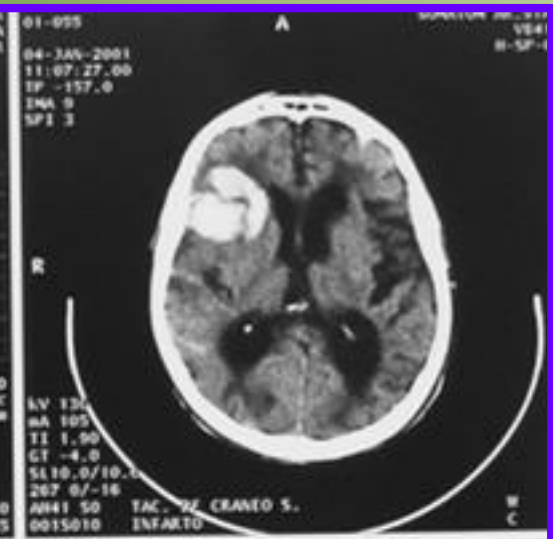
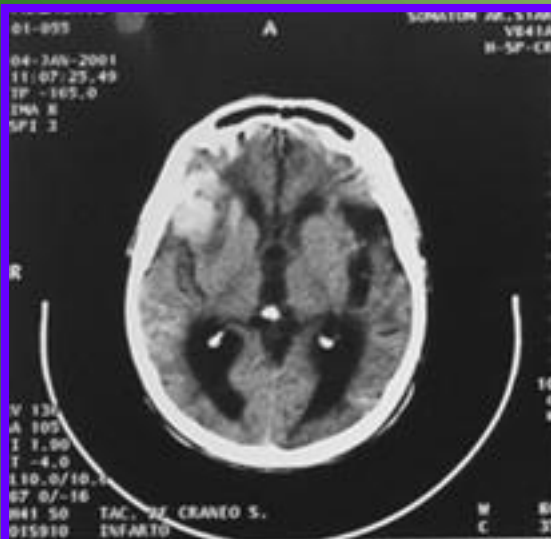


# Imágenes Hiperdensas



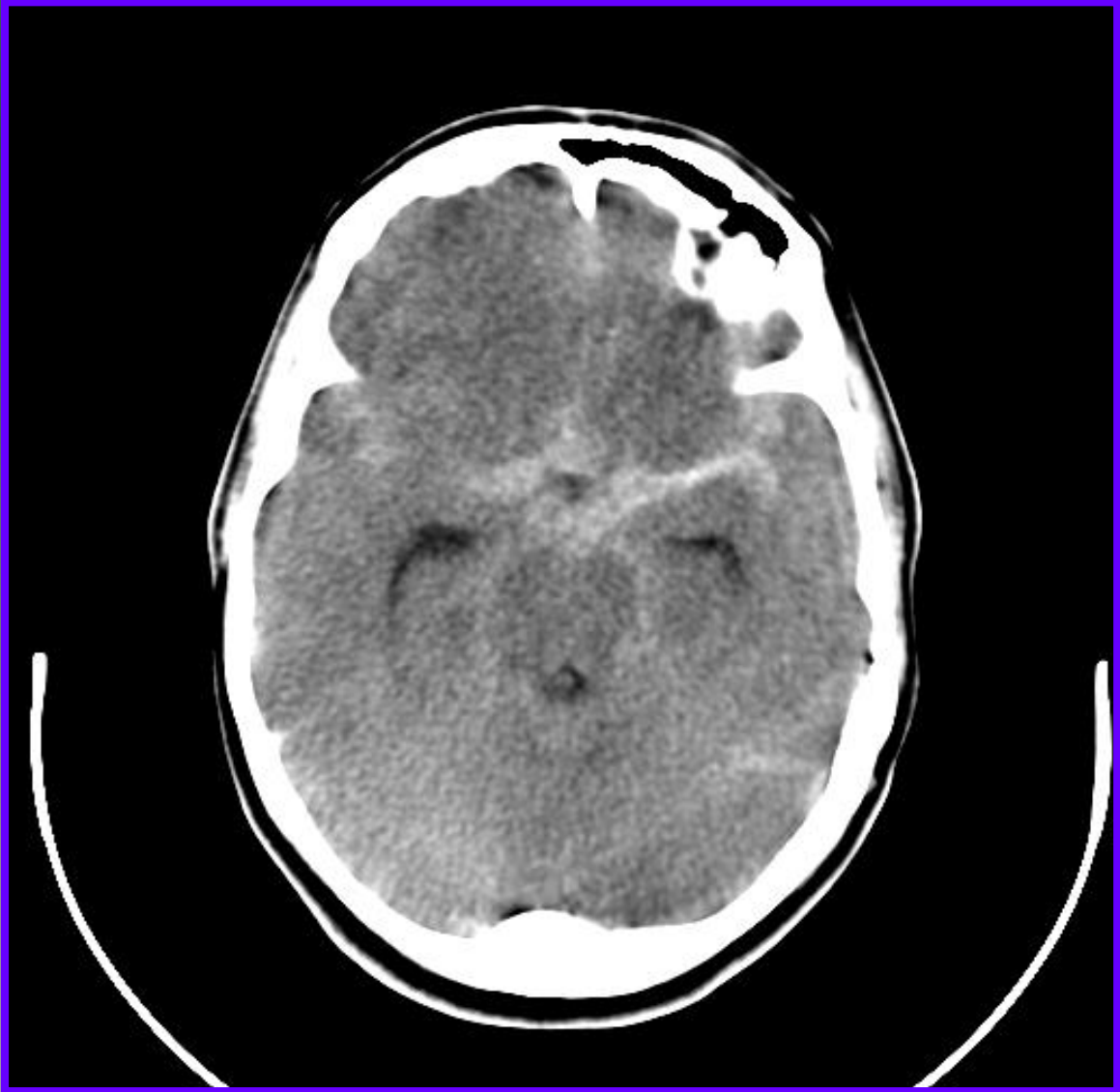


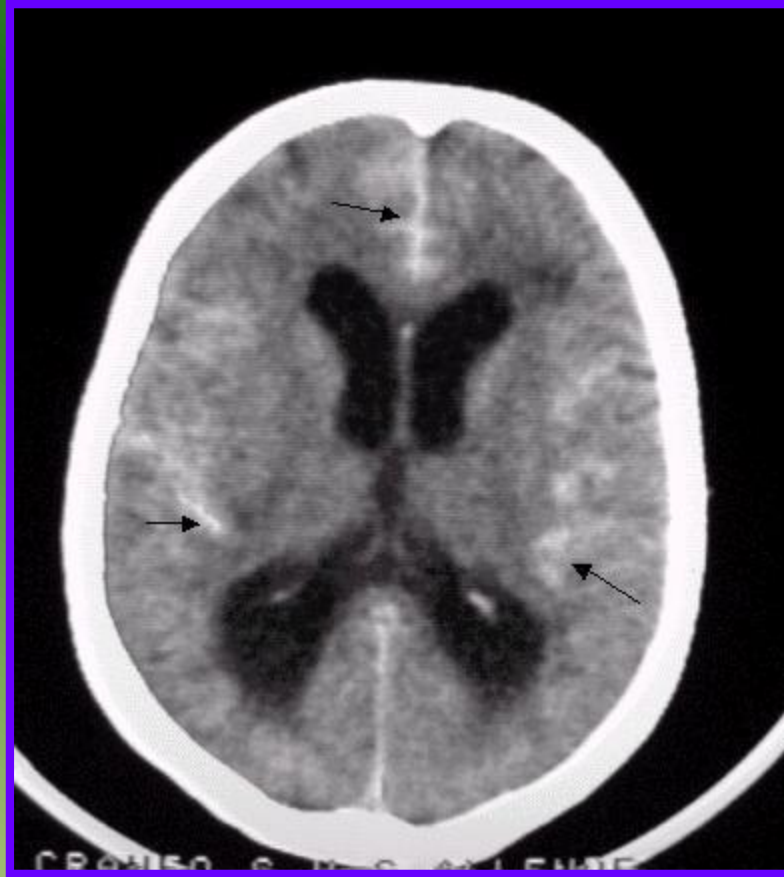Ganancia en  
densidad con la  
administración de  
contraste





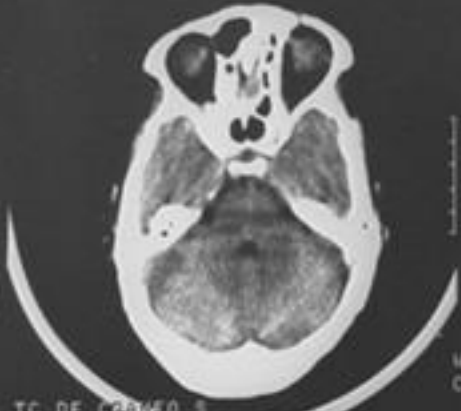






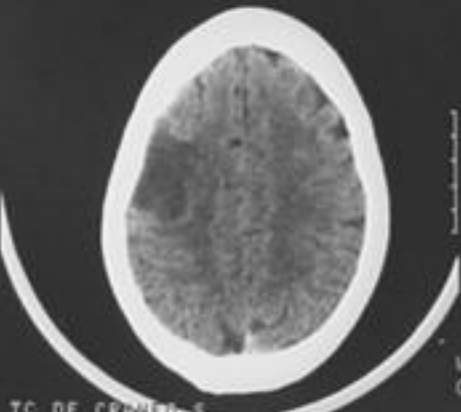
# Imágenes Hipodensas

ESTHER FUENTES M54A AH 01-556  
4-AUG-01 FRONT  
10:23:46  
DAB:111  
SCAN 8



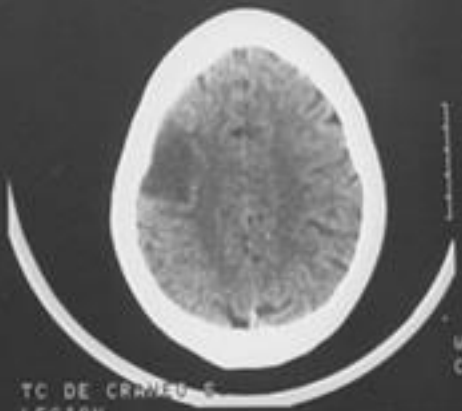
TC DE CRANEO S  
415 LESION

ESTHER FUENTES M54A AH 01-556  
4-AUG-01 FRONT  
10:31:30  
DAB:112  
SCAN 9



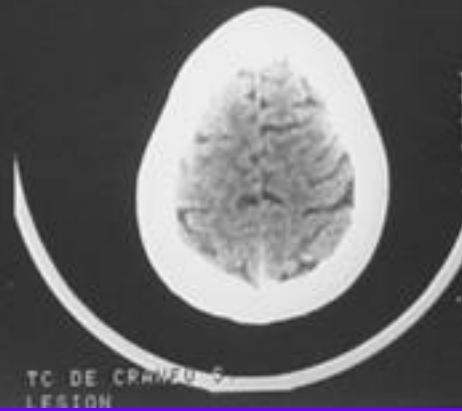
TC DE CRANEO S  
162 LESION

ESTHER FUENTES M54A AH 01-556  
4-AUG-01 FRONT  
10:29:47  
DAB:111  
SCAN 8

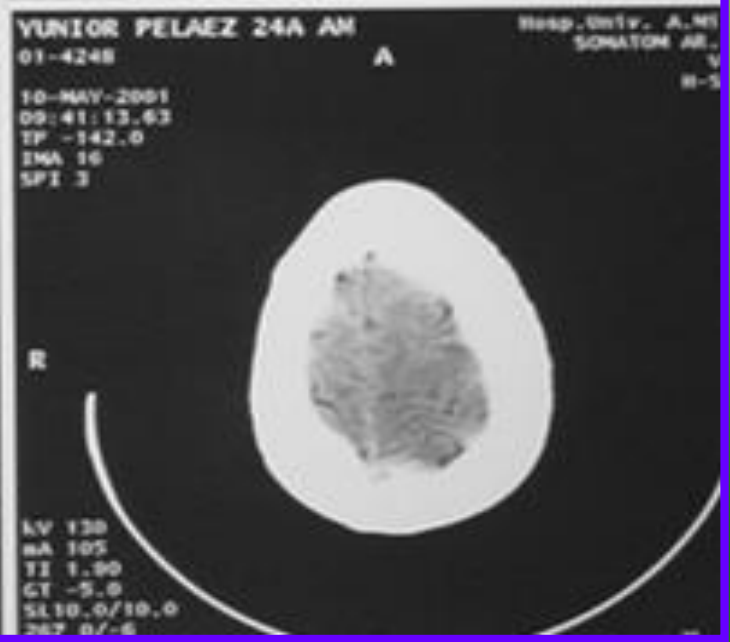
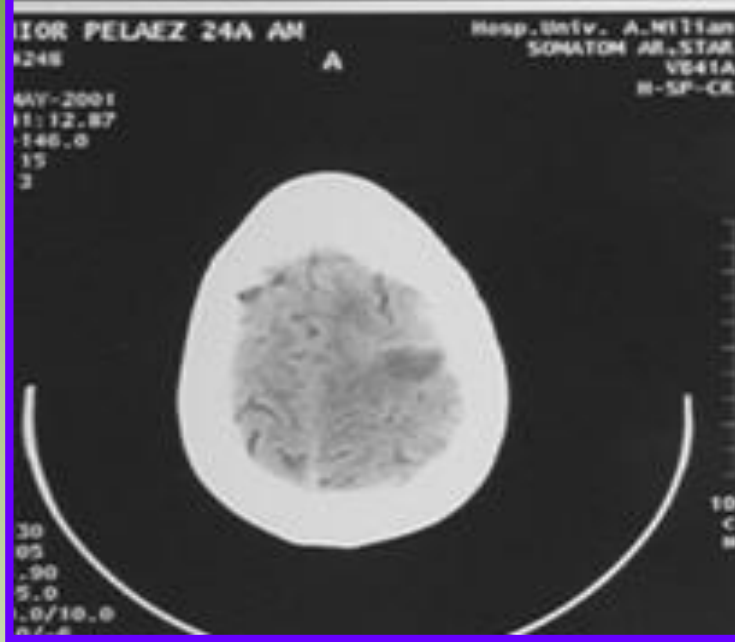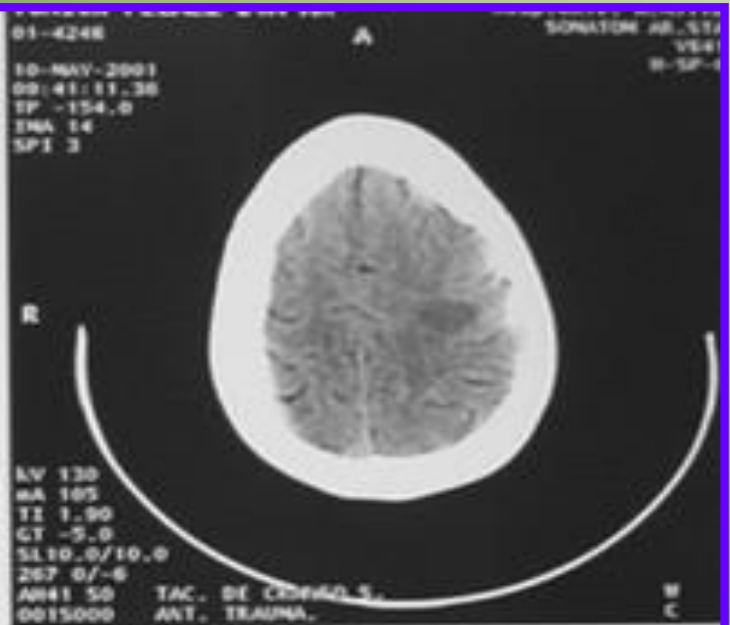
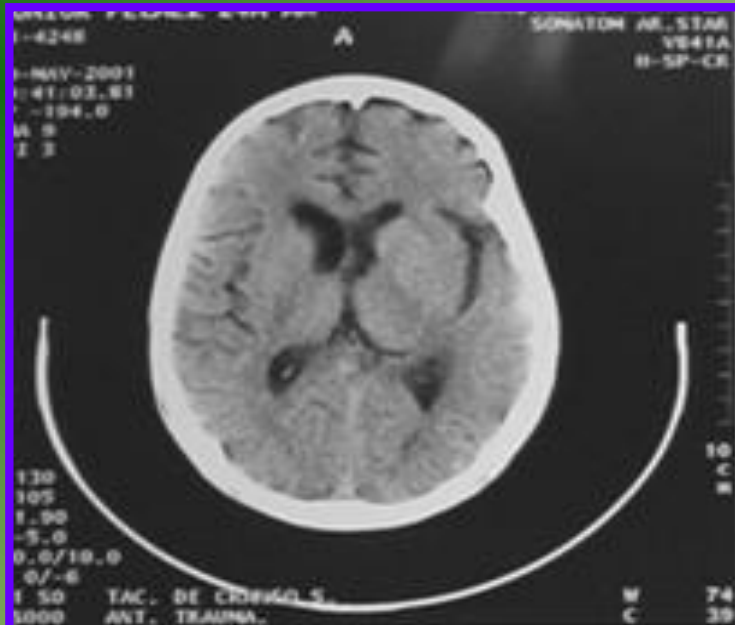


TC DE CRANEO S  
415 LESION

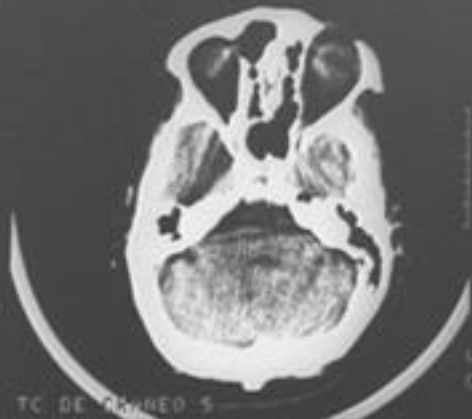
ESTHER FUENTES M54A AH 01-556  
4-AUG-01 FRONT  
10:32:40  
DAB:114  
SCAN 11



TC DE CRANEO S  
162 LESION

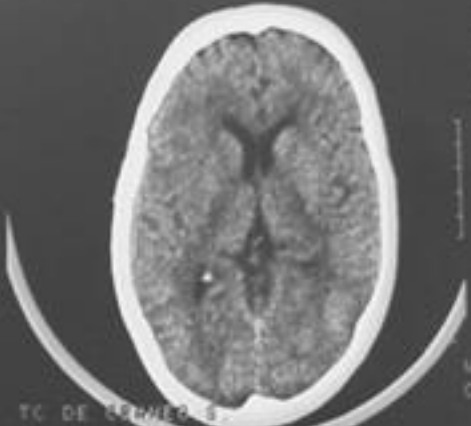


ESTHER FUENTES65A ARC 01-412  
20-JUL-01 FRONT  
00:31:47  
DAI:012  
SCAN 7

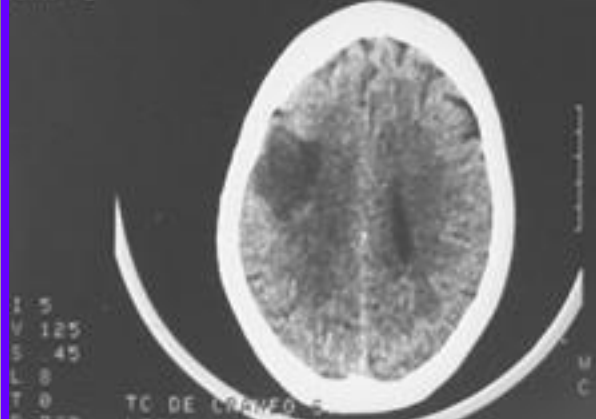


TI 5  
KV 125  
WS 45  
SL 8  
GT 0  
TR 419  
CORPUS LP  
ESTHER FUENTES65A ARC 01-412  
20-JUL-01 FRONT  
00:36:42  
DAI:018  
SCAN 9

ESTHER FUENTES65A ARC 01-412  
20-JUL-01 FRONT  
00:32:49  
DAI:015  
SCAN 8

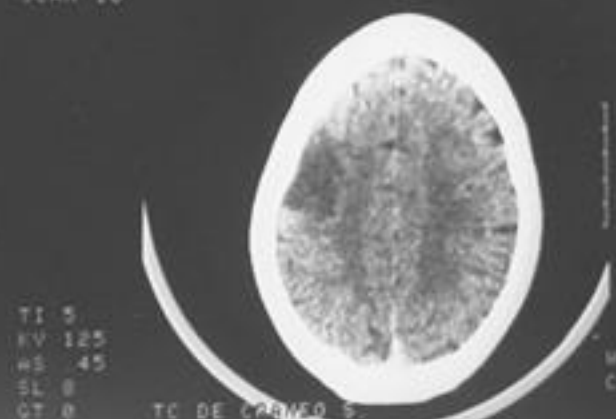


TI 5  
KV 125  
WS 45  
SL 8  
GT 0  
TR 387  
CORPUS LP  
ESTHER FUENTES65A ARC 01-412  
20-JUL-01 FRONT  
00:37:38  
DAI:019  
SCAN 10



TI 5  
KV 125  
WS 45  
SL 8  
GT 0  
TR 367

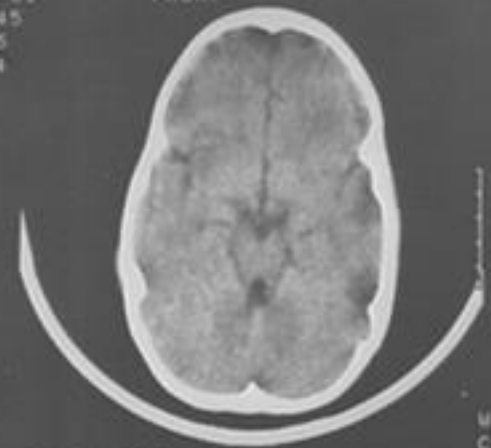
R I G H T  
5 CM  
M 80  
C 33



TI 5  
KV 125  
WS 45  
SL 8  
GT 0  
TR 388

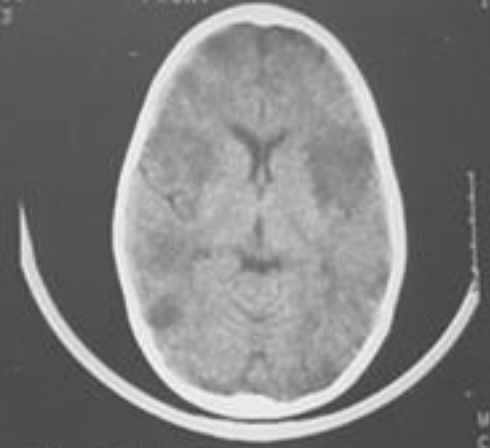
R I G H T  
5 CM  
M 80  
C 33

ETSER PEREZ 3A H. I. 01-883 OC2  
5-SEP-01 FRONT 1.66B  
09:23:45 H/SP  
DAI: 045  
SCAN 4



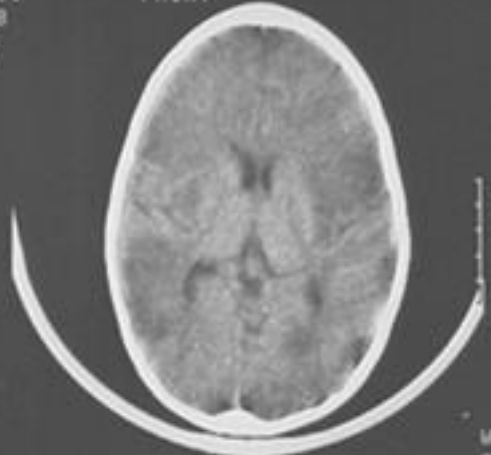
TI 5  
KV 125  
AS .45  
SL 8  
GT 12 TC. CRANEO S.  
TP. 450 EVOLUTIVO  
M 80  
C 7

ETSER PEREZ 3A H. I. 01-883 OC2  
5-SEP-01 FRONT 1.66B  
09:24:53 H/SP  
DAI: 047  
SCAN 6



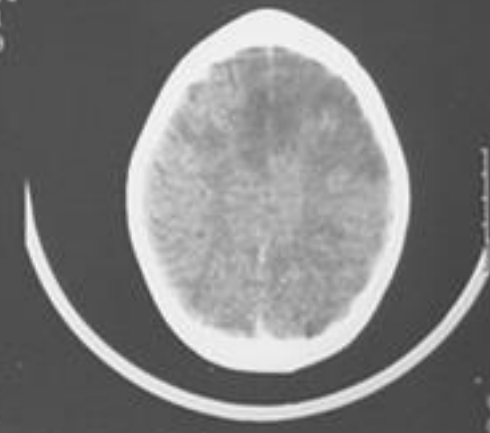
TI 5  
KV 125  
AS .45  
SL 8  
GT 12 TC. CRANEO S.  
TP. 434 EVOLUTIVO  
M 80  
C 7

SURATOR LK HUSP. "ARMANDO RILIAN" V.C.  
ETSER PEREZ 3A H. I. 01-883 OC2  
5-SEP-01 FRONT 1.66B  
09:25:28 H/SP  
DAI: 048  
SCAN 7



TI 5  
KV 125  
AS .45  
SL 8  
GT 12 TC. CRANEO S.  
M 80  
C 7

SURATOR LK HUSP. "ARMANDO RILIAN" V.C.  
ETSER PEREZ 3A H. I. 01-883 OC2  
5-SEP-01 FRONT 1.66B  
09:27:13 H/SP  
DAI: 051  
SCAN 10



TI 5  
KV 125  
AS .45  
SL 8  
GT 12 TC. CRANEO S.  
M 80  
C 8

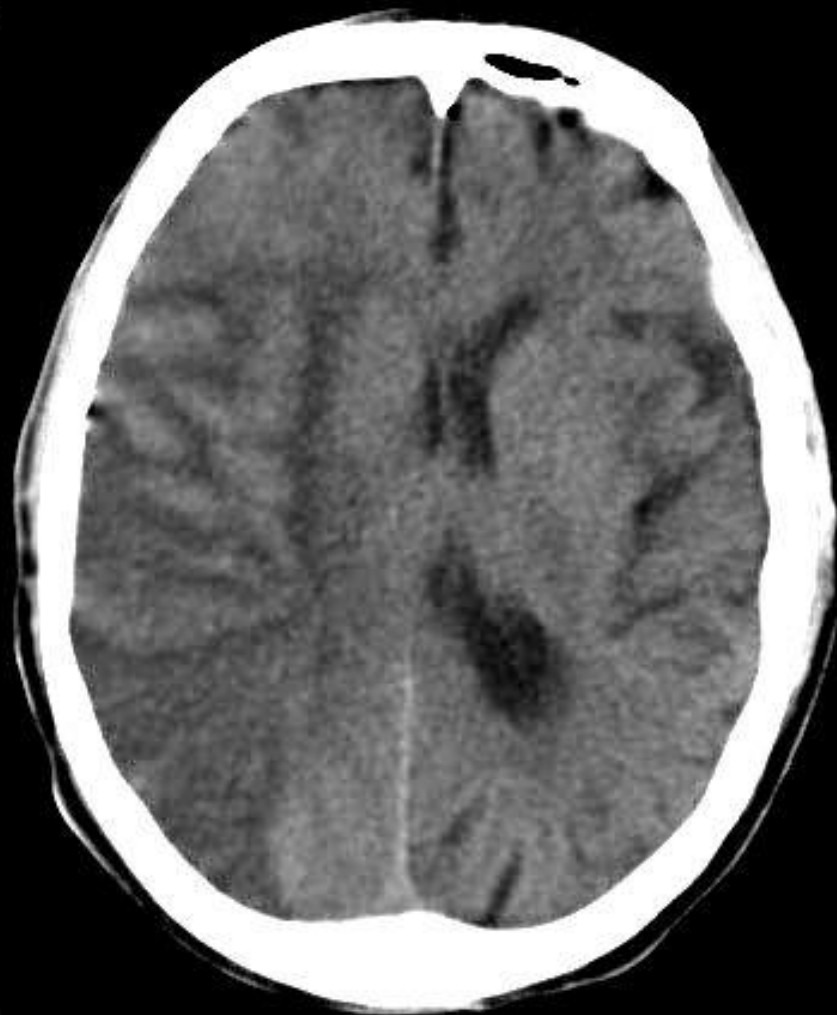

ROLANDO CRESPO 65A C.H  
05-710  
9:35  
24-1-2005  
Img # 11

AH

Hosp.Univ. A.Milian  
SOMATOM AR.STAR

R



10 cm

TC 105  
EX 200  
ET 1900  
GT -19.00  
KUP 000100

TAC. DE CRANEO S.

LESION CERB.

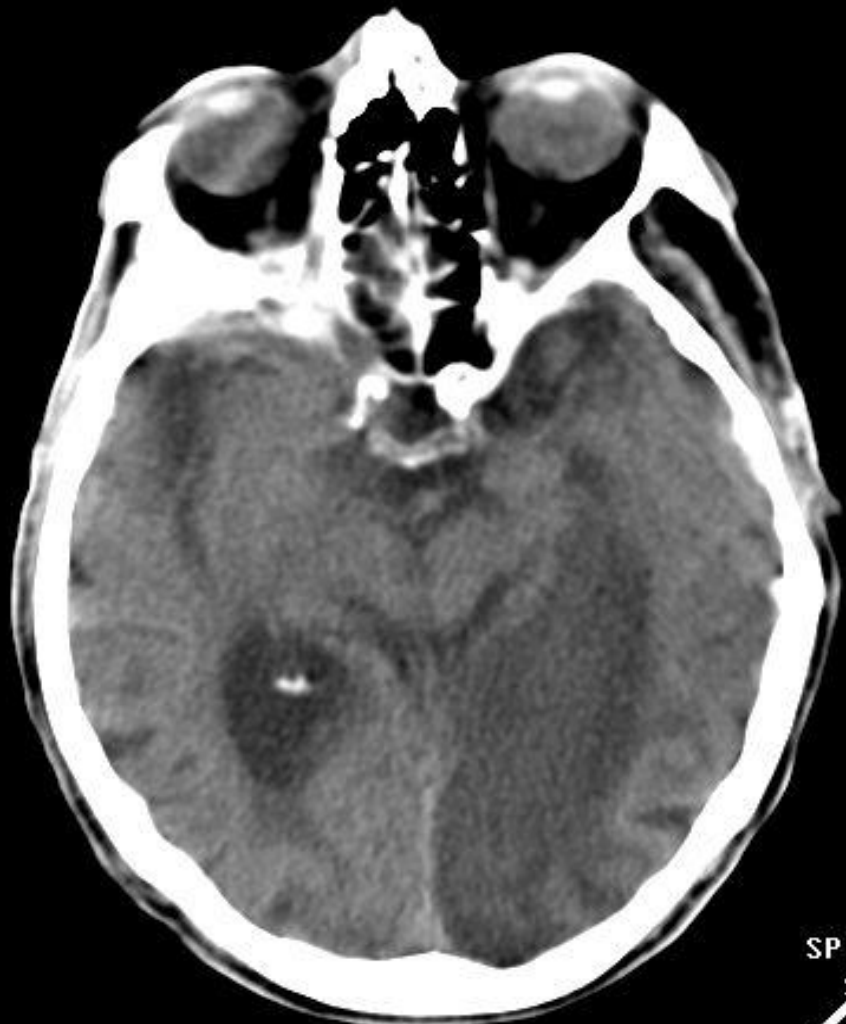CP 1:1  
SP -524.0  
SL 10.0  
W 80  
C 35

GERARDO PEREZ 85A AMC  
05-968  
10:4  
31-1-2005  
Img # 8

A

Hosp.Univ. A.Milian  
SOMATOM AR.STAR

R



10 cm

TC 105  
EX 200  
ET 1900  
GT 0.00  
KUP 000130

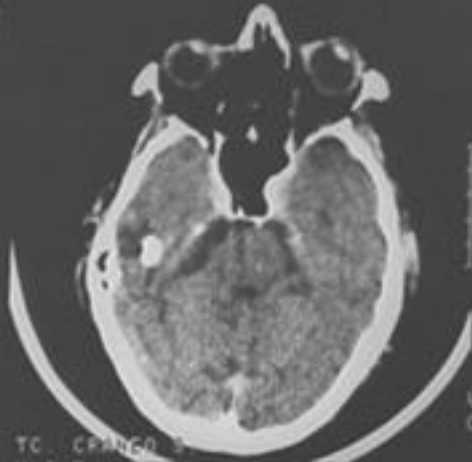
TAC. DE CRANEO S.

LESION

CP 1:1  
SP -574.0  
SL 10.0  
W 111  
C 35

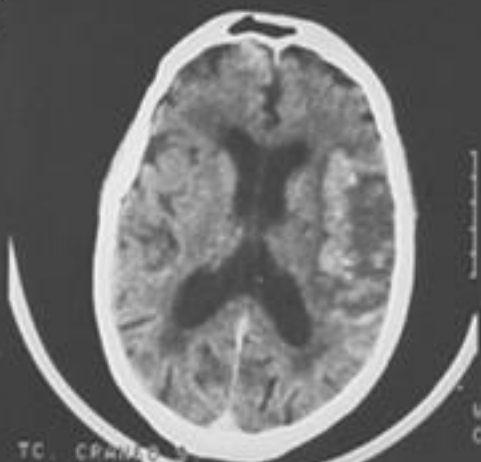
# Imágenes Hiperdensas e Hipodensas

ANTONIO REYES 77A AM 01-817  
30-AUG-81 FRONT  
08-30-47  
DAI:022  
SCAN 2



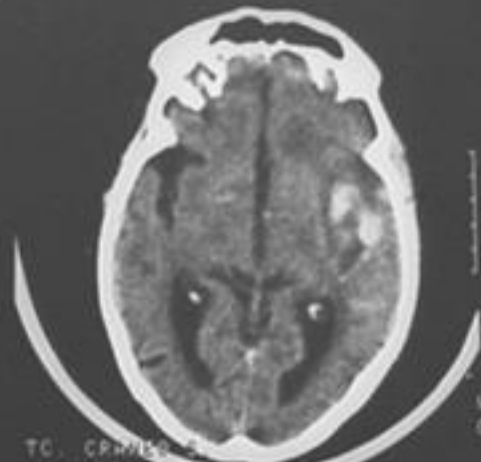
TI 5  
KV 125  
AS 45  
SL 0  
GT 0 TC. CRANIO  
TP 411 H.I.P

SUNWTON LE  
ANTONIO REYES 77A AM 01-817  
30-AUG-81 FRONT  
08-33-30  
DAI:026  
SCAN 6



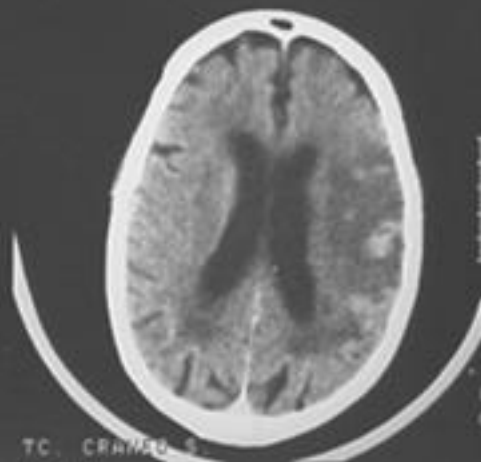
TI 5  
KV 125  
AS 45  
SL 0  
GT 0 TC. CRANIO  
TP 375 H.I.P

ANTONIO REYES 77A AM 01-817  
30-AUG-81 FRONT  
08-32-49  
DAI:025  
SCAN 5



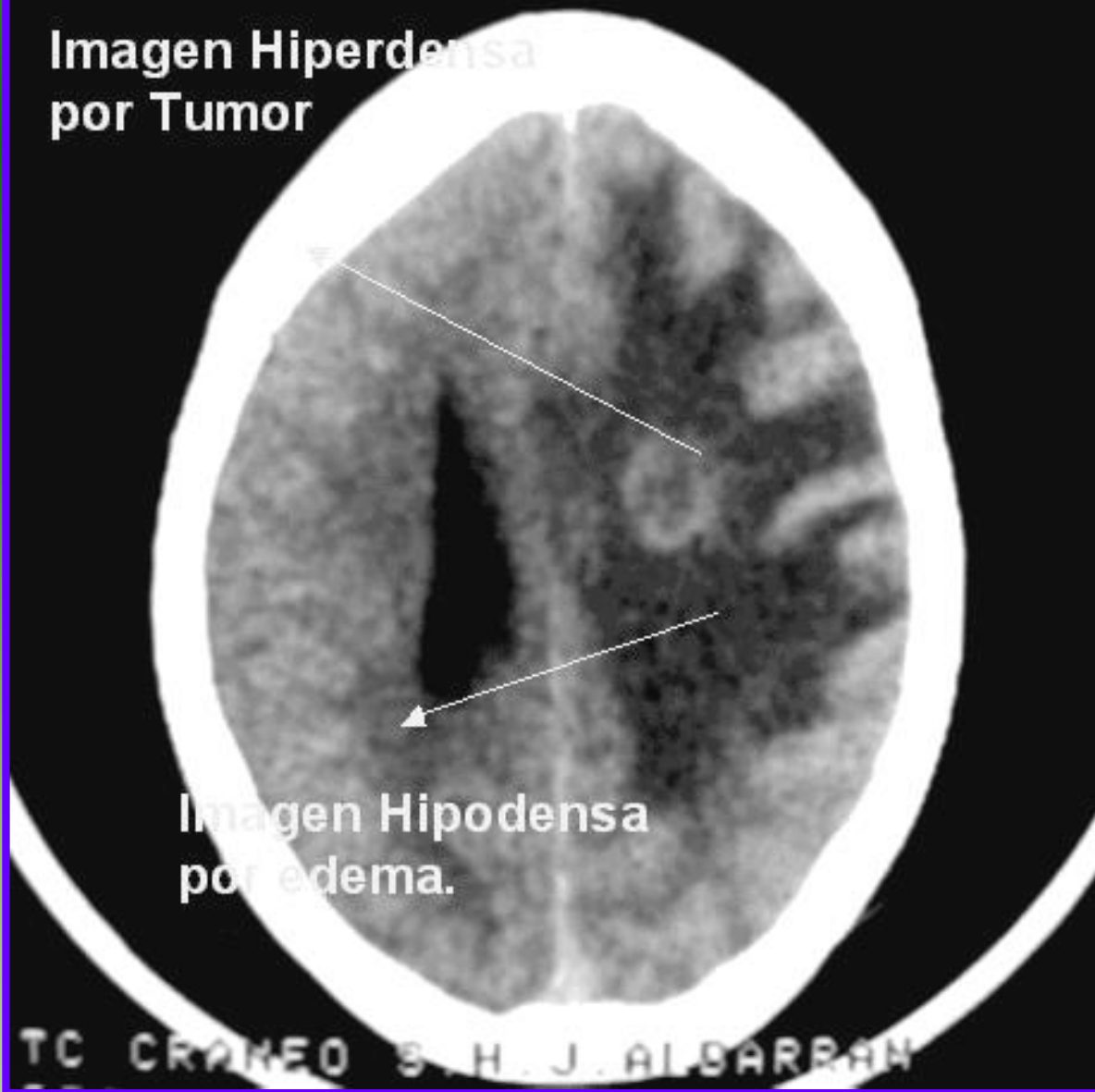
TI 5  
KV 125  
AS 45  
SL 0  
GT 0 TC. CRANIO  
TP 391 H.I.P

SUNWTON LE  
ANTONIO REYES 77A AM 01-817  
30-AUG-81 FRONT  
08-34-04  
DAI:027  
SCAN 7



TI 5  
KV 125  
AS 45  
SL 0  
GT 0 TC. CRANIO

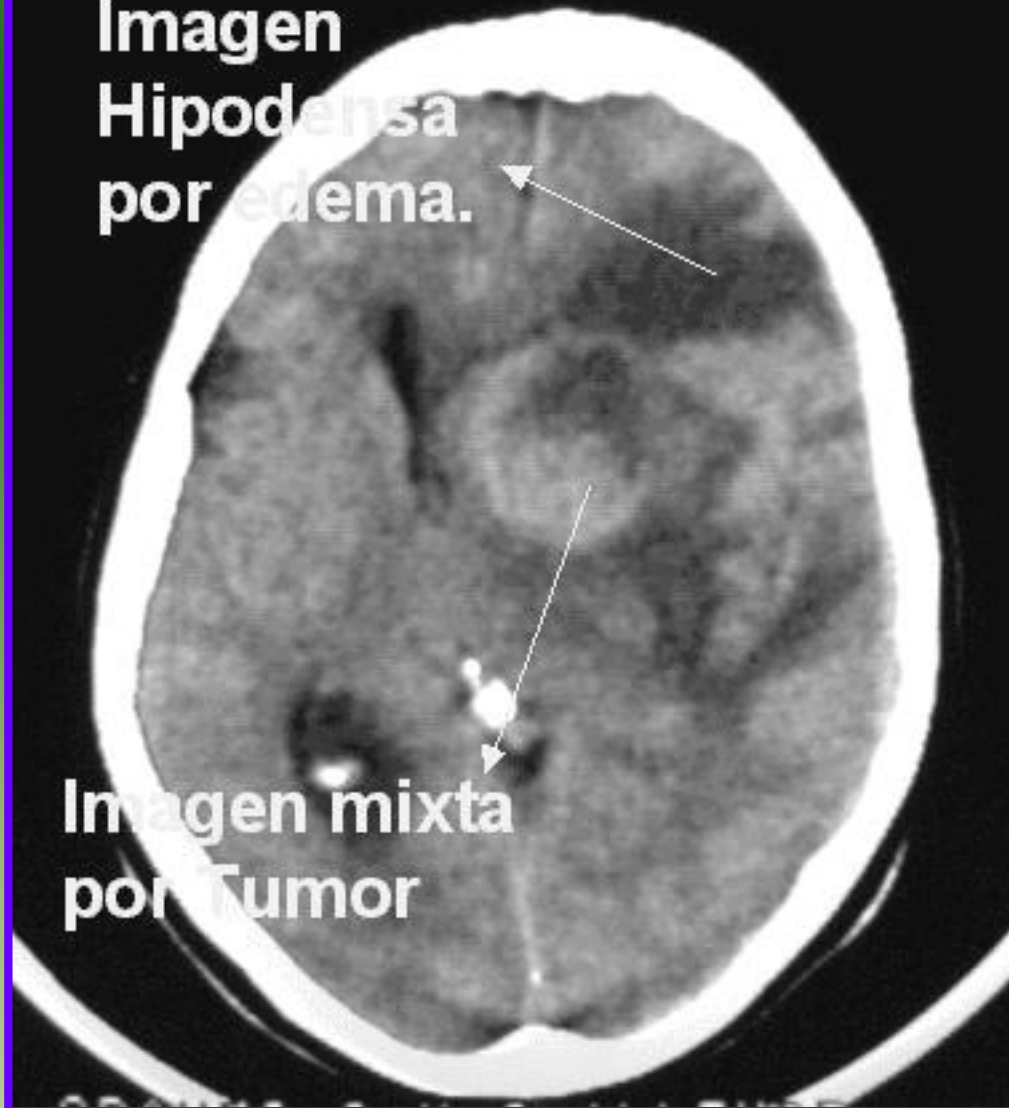**Imagen Hiperdensa  
por Tumor**



**Imagen Hipodensa  
por edema.**

TC CRANEO S. H. J. ALBARRAN

**Imagen  
Hipodensa  
por edema.**



**Imagen mixta  
por Tumor**

# Lesiones Líticas en TAC

